



Pleural effusions of malignant etiology: diagnostics, treatment and quality of life

Miloš KOLEDIN
Dejan ĐURIĆ
Aleksandar MILOVANČEV
Milorad BIJELOVIĆ
Borislav BAROŠ

BACKGROUND: *Pleural effusions of malignant etiology develop in the terminal stage of a malignant disease. They induce a further deterioration of a patient's bad general health condition, making him hospital ridden due both to his serious general state and the need for successive pleural aspirations. It is crucial to define the etiology of a pleural effusion and perform pleurodesis in the most effective, comfortable and humane way for a patient. Among the variety of pleurodesis agents having been used worldwide so far, talc has emerged as the most efficient, the safest and low cost pleurodesis agent.*

METHODS: *In period 1992-2000, pleurodesis was performed in 317 patients with a malignant pleural effusion at the Thoracic Surgery Clinic in Sremska Kamenica. The talc suspension was introduced intrapleurally through a thoracic drain after the effusion had been completely evacuated. The patients in whom the cytological analysis of the pleural puncture sample failed to enlighten the etiology of the effusion were submitted to thoracoscopy. Pleurodesis is considered effective if no relapse occurs within 3 months after the intervention.*

RESULTS: *Pleurodesis was assessed as effective in 310 patients of our series (98%). The mean duration of the pleural drainage was 5.4 days. Regarding complications, we had fever, pain and separation of the effusion. No deaths were induced by the procedure of pleurodesis itself. Afterwards the patients came for an ambulatory follow-up until they died.*

CONCLUSION: *In our opinion, talc pleurodesis is the most effective, humane, the low cost and safest method for obliterating the pleural space in malignant pleural effusions. The method has the efficacy of over 95%. Thoracoscopy, as well as pleurodesis have a low risk of complications. The quality of life in these patients is significantly improved 30 days after pleurodesis since the majority of the symptoms either completely disappeared, or their intensity decreased a lot, regarding in particular suffocation, cough and pain as the major symptoms in these patients.*

KEY WORDS: *Pleural Effusion, Malignant+diagnosis+therapy; Pleurodesis; Thoracic Surgery, Video-Assisted*
Archive of Oncology 2001,9(1):3-7©2001, Institute of Oncology Sremska Kamenica, Yugoslavia

INSTITUTE FOR LUNG DISEASE, SREMSKA KAMENICA,
YUGOSLAVIA

INTRODUCTION

Developing as a result of either transudation or exudation of the fluid on the surface of the pleura, a pleural effusion is a clinical sign of a systemic or pleural disorder. It impairs the lung function in a mechanic way, preventing the lungs to expand and resulting in dyspnea. Chronic presence of pleural effusion induces atelectasis and entrapment of the lungs, as well as intercurrent infections.

In any transudate, regardless its etiology, it is possible to treat, more or less effectively, the underlying disease, achieving resorption of the effusion from the pleura. However, it is still impossible to treat malignant effusions quite efficiently since the underlying disease has already so advanced that any treatment is usually inefficient and useless (1,2). Chronic malignant pleural effusions are commonly induced by lung cancer in males or by breast cancer in females. They are less frequently caused by the malignant lymphoma, malignant mesothelioma or ovarian, renal and colon cancers (3,4). The effusion develops due to dissemination of metastatic lesions over the visceral and parietal pleura, where malignant cells can be detected. In case of the malignant lymphoma, malignant cells are not found in the effusion itself, since it is a consequence of the lymph-flow obstruction by tumor tis-

Address correspondence to:

Dr Miloš Koledin, Institute for Lung Disease, Institutski put 4, 21204 Sremska Kamenica, Yugoslavia

The manuscript was received: 31. 10. 2000.

Provisionally accepted: 04. 01. 2001.

Accepted for publication: 12. 03. 2001.

sue. Even lung cancer may induce a malignant pleural effusion lacking malignant cells due either to an obstruction of the lymph-flow by the tumor tissue, or to the bronchus obstruction by obstructive pneumonitis of the respective lung portion (5,6).

Malignant pleural effusions reoccur shortly after they are evacuated, so dyspneic symptoms sometimes persist for months, practically over a patient's lifetime.

The diagnosis of a chronic malignant pleural effusion is established by thoracentesis with a cytological analysis of the pleural aspiration sample, "blind" needle biopsy of the pleura and standard or video-assisted thoracoscopy with the pleural biopsy. The cytological assay of the pleural aspiration sample can confirm the involvement of the effusion by malignant cells in about 50% of the cases. Similar results are obtained by the "blind" needle biopsy of the pleura, while the combination of the latter two methods is effective in about 60% of the cases (7). The highest 80-100% score is achieved by thoracoscopy (8,9).

Thoracoscopy, particularly the video-assisted one (VATS), developed in the late 80's, represents a high-potential diagnostic and therapeutic procedure. The basic condition for thoracoscopy is that an artificial pneumothorax can be produced in a selected patient. It can be performed in either the local or general anesthesia. At our Thoracic Surgery Centre we prefer to do thoracoscopy in general anesthesia since the biopsy taking in local anesthesia may be very painful for a patient. VATS has been found to have considerable comparative advantages in regard to a standard thoracoscopy (Figure 1) (10-12).

pleural biopsy only	-	in general anesthesia exclusively 2-3 incisions expensive equipment
STANDARD THORACOSCOPY THORACOSCOPY	+	VIDEO-ASSISTED better chances for diagnostic and therapeutic techniques can be well presented and
simple ambulatory procedure local anesthesia incision documented		

Figure 1. Standard and video-assisted thoracoscopy: comparative features

Video-assisted diagnostics has been performed at the Institute since February, 1996 when the needed surgical equipment was acquired. VATS enables better exploration of the pleural region than standard thoracoscopy due to a number of the working canals provided, which enable better and more accurate sampling of both the parietal pleura and the mediastinum. On the other hand, the surgery is larger in extent than a standard thoracoscopy.

Malignant pleural effusions may be evacuated by any of the following procedures:

1. thoracentesis
2. thoracic drainage

3. systemic chemotherapy
4. thoracic drainage with pleurodesis
5. thoracotomy with pleural abrasio or pleuroectomy

Thoracentesis is a simple outpatient procedure with immediate, though short-term effects. The majority of patients develop relapses shortly afterwards, so the effectiveness of the method is assessed to be only 5%. On the other hand, due to a high protein content of the effusion, successive evacuating pleural aspirations may induce hypoproteinemia and the resulting decrease of the plasma oncotic pressure and, finally, an increasingly faster effusion formation. In the terminal stage of the disease, successive protein losses cause further weakening of an organism exhausted by lung cancer, having already reached the catabolic metabolism stage. Successive and frequent thoracentesis may be accompanied by serious complications, such as pleural empyema, artificial pneumothorax, bronchopleural fistula and separation of the pleural content, resulting in a formation of a number of separate collections. The pleural aspiration may confirm the existence of an effusion, enlighten its etiology and relapsing potential and define the chances for reexpansion of the lungs to follow the evacuation.

Drainage of the thorax without pleurodesis is effective in about 20% of the cases.

Systemic chemotherapy is mostly ineffective, except in rare cases of small-cell lung cancer, breast cancer and malignant lymphoma.

Radiotherapy is only effective in radiosensitive tumor types; intrapleural radioisotope application is not performed due to its inefficiency and a high risk of irradiation (a high rate of irradiation-induced pneumonitis and very high costs of the intervention).

Thoracotomy with pleuroectomy or pleural support is hardly ever performed due to exceptionally high morbidity and mortality rates on one hand, and poor effects on survival on the other.

In pleurodesis, pleural adhesions and obliteration of the pleural space can be produced by the following agents: talc powder or suspension; tetracycline and its derivatives: doxycycline, minocycline; anti-neoplastic drugs: bleomycin, cisplatin, doxorubicin, 5-fluorouracil, meclorethamine, mitomycin etc; sclerosing agents: alcohol, formaldehyde, glycerin, hypertonic dextrose or glucose, salt, iodineform, kaolin, urea, quinacrine, silver-nitrate etc; immunomodulators: *Cerynebacterium parvum*, BCG, *Lactobacillus casei* extract, cytokine-beta and gamma interferon, interleukine-2 and some others; fibrinous glue: tissucol; corticosteroids.

Talc, tetracycline and bleomycin have nowadays been widely accepted and commonly used.

Tetracycline has been a standard pleurodesis agent over the recent 15 years, particularly in the USA, administered by an

intrapleural injection via a thoracic drain in the dose of 20mg/kg b/w. The efficiency of tetracycline decreases gradually in time, and so does the effectiveness of pleurodesis, falling to about 50%. Two additional major disadvantages of tetracyclines have been noticed as well: firstly, unlike other sclerosing agents, they induce a prolonged exudation of the pleura, thus elongating the time of draining; secondly, instillation of the tetracycline solution produces a severe pain that is hardly relieved by analgesics (17). Bleomycin is a cytotoxic agent, used for the purpose of pleurodesis in the dose of 1mg/kg b/w. It is also administered by instillation through a thoracic drain. Once it is instilled into the systemic circulation, about 45% of the dose is resorbed, being rather disadvantageous because many patients consequently develop pulmonary fibrosis. Undesirable side effects of bleomycin are severe pains, fever, nausea with vomiting and hypertension, registered in almost all patients. Additionally, bleomycin is the most expensive pleurodesis agent. Bleomycin induced pleurodesis has the efficiency of about 87% (18).

Unlike tetracyclines and bleomycin which get resolved in the pleural space, resorbed into the systemic circulation and excreted out of an organism, talc is insoluble, retained in the pleura, unresorbed and therefore unexcreted from an organism. The effects achieved by talc pleurodesis are long lasting since the presence of talc produces a constant stimulation to the pleura, resulting in the development of rather potent and diffuse adhesions. On the other hand, pain and fever develop much less frequently than with other sclerosing agents.

However, talc pleurodesis is not, free of complications, such as empyema of the pleura, pneumonitis, pulmonary edema and ARDS. Regarding cardiovascular complications like arrhythmia, cardiac arrest, myocardial infarction and hypertension, it can hardly be decisively said whether they are due to the surgery or to talc effects (19-20).

MATERIALS AND METHODS

From 1992 to 1999 talc pleurodesis was performed in 317 patients with malignant pleural effusion, at the Thoracic Surgery Center of the Institute for Lung Diseases in Sremska Kamenica.

In our study we included patients with (indications): presence of a fast collecting large pleural effusion which requires frequent successive thoracentesis evacuating abundant effusion content; subjective and objective improvement of a patient's general condition following thoracentesis; total reexpansion of the lungs expected after draining; Karnofsky index not lower than 50%; expected survival of 30 days or longer.

We excluded patients with (contraindications): bad general condition of a patient - Karnofsky index lower than 50%; expected survival shorter than 30 days; „captured lung“ syndrome; atelectasis

due to an endobronchial obstruction; thickened visceral pleura; empyema.

The presence of malignant cells in the pleural effusion was verified in 240 patients (59.7%), while in 162 patients (40.3%) the diagnosis of a malignant pleural effusion was established either by a standard or video-assisted thoracoscopy (Figure 2).

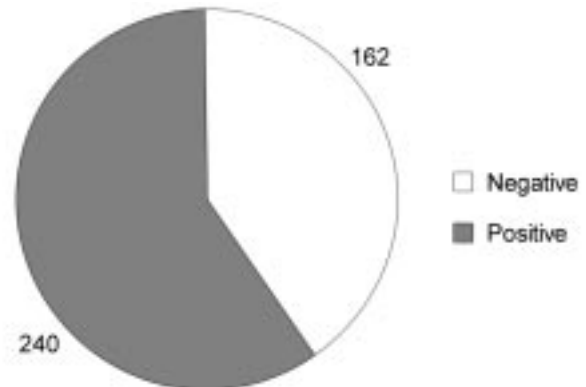


Figure 2. Cytology examination of pleural effusions

The tumor types in patients submitted to pleurodesis are reviewed in the graph and table below.

Table 1. Histologic tumor types in patients submitted to pleurodesis

Histologic tumor type	Number
Adeno Ca	170
Ca mammae	89
Ca epidemoides pulm.	48
Mesothelioma malignum	35
Ca microcellare pulm.	33
Other types	24
Total	402

All patients with no evidence of malignant cells in the pleural effusion had thoracoscopy in total anesthesia performed in the operating room, applying two-volume endotracheal tubes. On the operating table the patient was positioned into the lateral decubitus and the surgical field was prepared as for thoracotomy. Until a videothoracoscopy was introduced in 1996, a standard thoracoscopy with a rigid Storz thoracoscope had been performed, but since then an Olympus videothoracoscope has been in use. The effusion had been evacuated before the pleural space was inspected and both the visceral and parietal pleura sampled for the purpose of establishing the diagnosis. After an intraoperative histologic verification of the disease been obtained, a thoracic drain of 22F was introduced intrapleurally, serving for instillation of 2g of talc resolved in 100ml of sterile natrium-chloride solution and 10ml of a local anesthetic (2% Cystocain).

The talc suspension contained a natural magnesium-silicate (with a slight admixture of aluminum-silicate and no asbestos). The talc was sterilized in a gas sterilizer for two hours, with ethylene-oxide at the temperature of 50°C and the pressure of 2.2 atmospheres. After talc instillation the drain was closed and the patient kept

changing his bed posture at 15-minute intervals for the following six hours in order to achieve talc distribution throughout the entire pleura. Then the drain was connected with an active suction system in order to achieve a total reexpansion of the lungs.

The dynamics of re-expansion was radiologically controlled. The patient was radiologically controlled daily after the drain had been introduced. When secretion had decreased (less than 100ml per day) or completely ceased, the drain was removed and the patient dismissed from hospital. After the discharge, the patients were clinically and radiologically controlled throughout their lifetime. Pleurodesis was considered effective if no effusion relapse occurred within the following three-month period.

RESULTS

Pleurodesis was assessed as effective in 391 (97%) patients with a malignant pleural effusion, while in 11 patients (3%) the effusion reaccumulated in the pleura in less than three months after pleurodesis (Figure 3).

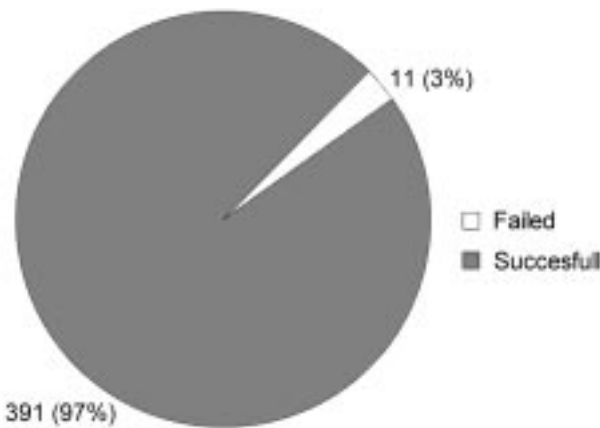


Figure 3. Effectiveness of pleurodesis

Bilateral pleurodesis was performed in 11 (3%) patients.

Thoracic drainage took the mean of 5.4 days, ranging from 2 to 21 days. Due to an incomplete reexpansion of one lung, additional drains were placed in eight patients, resulting in a reexpansion of the entire lung; however, the drainage time was thus prolonged to 9-21 days.

The procedure of pleurodesis was accompanied with the following complications: pain, fever and separation of the pleural effusion.

Fever developed in 73% of the patients, rising to the mean level of 37.8C (37-39), which was regarded as a certain sign of the development of pleurisy, leading to pleural adhesions formation and obliteration of the pleural space, i.e. to pleurodesis. All patients developed moderate pain.

Pain and fever were only present immediately after the intervention (0-2nd postoperative day). The pain which develops afterwards was rather mild and mostly associated with the drain pos-

ture. Both symptoms were relieved by analgo-antipyretics administered parenterally on the day of surgery and perorally afterwards.

Eight patients developed separation of the pleural effusion, in three patients in the upper parts of the pleural space, while in five patients it was a separate lateral collection which couldn't be controlled by the drain. This was resolved by additional drains and another. In all patients the repeated pleurodesis was successful. After the discharge from the Thoracic Surgery Centre, all the patients had regular monthly controls during their lifetime.

No serious, pleurodesis-induced complications (lung injuries, hemorrhage, respiratory failure, ARDS, pulmonary edema, empyema, cardiac disorder), nor deaths were registered.

DISCUSSION

Talc is widely used for pleurodesis in malignant effusions all over the world. A former presumption and fear that intrapleural talc instillation might induce pleural mesothelioma hasn't been confirmed. None of 46 patients who had undergone talc pleurodesis and were afterwards followed for 22-35 years by a Special Research Committee for Pneumoconiosis of the British Association of Chest Surgeons developed pleural mesothelioma or generalized pleural calcifications. Only one of them had pulmonary fibrosis. Similar observations were reported by Lange, Mortensen and Groth in 1988 (21).

The table below reviews the results of talc pleurodesis treatment of malignant pleural effusions reported by a number of authors (22). Pleurodesis effectiveness of 98% obtained in our series correlates well to the results reported by other authors.

Table 2. Talc pleurodesis in the treatment of pleural effusions: results

Author	Year	Method	Dose (g)	Effective/total (%)
Chambers	1958	solution	7-14	19/22(86)
Gingell	1965	spray	5	4/4 (100)
Bloomberg	1970	solution	1	22/22 (100)
Adler and Sayer	1976	solution	10	41/44 (93)
Harley	1979	spray	5-10	39/44 (89)
Weissberg	1980	spray	2	31/35 (89)
Todd	1980	spray	nepoznata	148/163 (90)
Sorensen and Svedsen	1984	solutin	10	9/9 (100)
Hamed	1989	spray	5	10/10 (100)
Aelony	1991	spray	2-5	34/39 (87)
Chri	1992	spray	2-5	35/39 (90)
Webb	1992	solutin	5	34/34 (100)
Hartman	1993	spray	3-6	20/21 (95)
Sanchez and Rodriguez	1993	spray	unknown	104/119 (87)
Kennedy	1994	solutin	10	35/44 (80)
Koledin	1999	solution	2	310/317 (98)

The quality of life has been compared prior and 30 days after pleurodesis. Major life-quality affecting symptoms reported by the patients (affecting their life quality prior and after pleurodesis) are reviewed in Tables 3 and 4.

Table 3. Symptoms prior to pleurodesis

Symptoms	None	Mild	Moderate	Severe
dyspnea	(8) 2%	(52) 13%	(161) 40%	(181) 45%
cough	(20) 5%	(92) 23%	(270) 67%	20 (5%)
pain	(72) 18%	(188) 47%	(142) 35%	0
loss of appetite	(48) 12%	(133) 33%	(173) 43%	12%(48)
prostration	(33) 8%	(93) 23%	(169) 42%	27%(108)
anxiety	(28) 7%	(241) 60%	(80) 20%	13%(52)
sleep difficulties	(12) 3%	(129) 32%	(221) 55%	10%(40)
decreased activity	0	(80) 20%	(293) 73%	7%(29)
impaired ability to perform housework	0	(113) 28%	(241)60%	12%(48)

Table 4. Symptoms 30 days after pleurodesis (1st control)

Symptoms	None	Mild	Moderate	Severe
dyspnea	96%(386)	0	2%(8)	2%(8)
cough	87%(350)	10%(40)	3%(12)	0
pain	80%(322)	17%(68)	3%(12)	0
loss of appetite	90%(362)	7%(28)	3%(12)	0
prostration	90%(362)	3%(12)	7%(28)	0
anxiety	86%(346)	10%(40)	2%(8)	2%(8)
sleep difficulties	83%(334)	17%(68)	0	0
decreased activity	95%(382)	5%(20)	0	0
impaired ability to perform housework	97%(390)	3%(12)	0	0

CONCLUSION

Our and other authors' results suggest that talc pleurodesis is a simple, effective and cheap procedure in the palliative treatment of patients with a malignant pleural effusion. At present, it is the most efficient method of obliterating the pleural space. In regard to the application of other sclerosing agents, this method is safe, efficient, humane, relatively painless and very cheap. With thoracoscopy and video-assisted thoracoscopy, talc pleurodesis ranges among the methods with a low risk of serious complications. The method has the efficiency over 90%, provided that a surgeon takes into account indications and contraindications for its application. Furthermore, talc pleurodesis bears a significantly lower risk of relapsing pleural effusions than other sclerosing agents and procedures.

REFERENCES

- Beljanski-Čonkić R, Antonić M, Čanak V. Effusions in pleural cavity. Saopštenja Instituta za plućne bolesti i tuberkulozu, Sremska Kamenica 1988;26(3-4):10.
- Keller SM. Current and future therapy for malignant pleural effusion. Chest 1993;103(1 suppl):63S-67S.
- Ignjačev Ž, Plavec V, Kanjuh V, Tucaković G. Special pathological anatomy. Beograd-Zagreb: Medicinska knjiga; 1976.
- Canto-Armengod A. Macroscopic Characteristic of Pleural Metastases Arising from the Breast and Observed by Diagnostic Thoracoscopy. Am Rev Respir Dis 1990;142:616-8.
- Đulžibarić J, Eri Ž. Cancer of the bronchi and pleural effusions. II Clinical aspects. Saopštenja Instituta za plućne bolesti, Sremska Kamenica 1986;24(3-4):95-9.
- Eri Ž, Đulžibarić J. Cancer of the bronchi and pleural effusions. I Pathological and morphological aspects. Saopštenja Instituta za plućne bolesti, Sremska Kamenica 1986; 24(3-4):101-5.
- Sayler WR, Eggleston JC, Erozan YS. Efficacy of pleural needle biopsy and pleural fluid cytology in the diagnosis of malignant neoplasms invading the pleura. Chest 1975;67:536-9.
- Dujmučić S. Surgical thoracoscopy. Beograd-Zagreb: Medicinska knjiga; 1949.
- Bloomberg AE. Thoracoscopy in diagnosis of pleural effusions. NY State J Med 1970;70:1974-7.
- Mack M, Aronoff R, Acuff T, Douthit M, Bowman R, Ryan W. Present Role of Thoracoscopy in the Diagnosis and Treatment of Diseases of the Chest. Ann Thorac Surg 1992;54:403-9.
- Hazelrigg SR, Nancavck SK, LoCicero J. Video-Assisted Thoracic Surgery Group data. Ann Thorac Surg 1993;56:1039-44.
- Demmy TL, Krasna MJ, Detterbeck FC, Kline GG, Kohman LJ, DeCamp MM Jr et al. Multicenter VATS experience with mediastinal tumors. J Thorac Cardiovasc Surg 1999;109:1198-204.
- Schlimmer P, Eich F, Schnabel D. Thoracoskopische Behandlung des Spontanpneumothorax mittels Fibrinpleurodese. Zent Bl Chir 1992;117:270-2.
- Robinson CL. Autologous Blood for Pleurodesis in Recurrent and Chronic Spontaneous Pneumothorax. Can J Surg 1987;30:428-9.
- Kennedy L, Sahn S. Pleurodesis for the treatment of pneumothorax and pleural effusion. Chest 1994;106:1215-22.
- Guerin J-C, Boniface E. Les methodes de pleurodese. Rev Prat (Paris)1990;40:1854-6.
- Hartman DL, Gaither JM, Kesler KA, Mylet DM, Brown JW, Mathur PN. Comparison of insufflated talc under thoracoscopic guidance with standard tetracycline and bleomycin pleurodesis for control of malignant pleural effusions. J Thorac Cardiovasc Surg 1993;105:743-7.
- Alfageme I, Moreno L, Huertas C, Vargas A, Hernandez J, Beiztegui A. Spontaneous pneumothorax: long-term results with tetracycline pleurodesis. Chest 1994;106:347-50.
- Rinaldo JE, Owens GR, Roger RM. Adult respiratory distress syndrome following intrapleural instillation of talc. J Thorac Cardiovasc Surg 1983;85:523-6.
- Bouchama A, Chastre J, Gaudichet A, Soler P, Gilbert C. Acute pneumonitis with bilateral pleural effusion after talc pleurodesis. Chest 1984;86:795-7.
- Lange P, Mortensen J, Groth S. Lung Function 22-35 Years After Treatment of Idiopathic Spontaneous Pneumothorax with Talc Poudrage or Simple Drainage. Thorax 1988;43:559-61.
- Kennedy L, Rusch V, Strange C, Ginsberg R, Sahn S. Pleurodesis using talc slurry. Chest 1994;106:342-6.
- Koledin M. Pleurodesis as a method of choice in the treatment of chronic pleural effusions. M.Sc. thesis. Novi Sad: Medical faculty Novi Sad; 1997.