



Konstantinos T. PAPAISIS¹
Panajiota BOURA²
Periklis FOUKAS³
Konstantinos A. DIMITRIADIS¹

Corticosteroid-induced Kaposi's sarcoma in a patient with systemic lupus erythematosus

ABSTRACT

We describe a 57-year old patient with SLE who developed Kaposi's sarcoma after the corticosteroid treatment. Discontinuation of corticosteroids was followed by a complete remission of the disease and two attempts to reintroduce corticosteroids resulted in exacerbations of Kaposi's sarcoma, which subsided again when the corticosteroid dosage was significantly reduced. The Kaposi's sarcoma lesions and the patient's peripheral blood were positive for HHV-8. The natural history of the disease indicates a direct relationship between corticosteroid-induced immunosuppression and Kaposi's sarcoma.

Key words: Kaposi's sarcoma; Corticosteroids; HHV-8

Archive of Oncology 2000,8(4):181-2©2000, Institute of Oncology Sremska Kamenica, Yugoslavia

¹2nd DEPARTMENT OF MEDICAL ONCOLOGY, THEAGENION CANCER INSTITUTE, THESSALONIKI, GREECE
²2nd MEDICAL CLINIC OF ARISTOTELIAN UNIVERSITY, HIPPOKRATION GENERAL HOSPITAL, THESSALONIKI, GREECE
³LABORATORY OF HISTOLOGY AND EMBRYOLOGY, SCHOOL OF MEDICINE, UNIVERSITY OF ATHENS, GREECE

INTRODUCTION

Kaposi's sarcoma (KS) is a vascular tumor with a high incidence among patients with the Acquired Immunodeficiency Syndrome (AIDS) (1). There have been several reports in the literature concerning the development of KS in patients treated with immunosuppressive medications for solid organ transplantation or autoimmune disease (2,3). Most of them had received corticosteroids (CS) and discontinuing therapy resulted in remission of the disease in most of the cases. However, a direct relationship between KS and CS treatment in autoimmune disease has not yet been established, since: 1) the onset of KS was unrelated to the dosage or the duration of the CS therapy, 2) spontaneous remissions of the disease have been reported, 3) KS has a very low incidence in patients with autoimmune disease (which would suggest a random coincidence) and 4) in some cases CS discontinuation did not result in a remission of KS.

The characterization of Kaposi's sarcoma associated herpes virus/human herpesvirus-8 (KSHV/HHV-8) as the causative agent for KS (4,5), strengthens the hypothesis that corticosteroid treatment may accelerate the progression or even induce the development of KS lesions, in patients who are already infected with the HHV-8 virus. The growth of KS seems to be controlled by host factors, and dysregulation of host immunity by autoimmune disease as well as CS-induced immunosuppression (where both the disease and the therapy interfere with the host immunity) may alter the natural history of the disease.

CASE REPORT

A 57-year-old woman, with a four-year history of systemic lupus erythematosus (SLE), developed autoimmune haemolytic anemia and was treated with methylprednisolone (32 mg/day). Anemia remitted, but three months later she noticed a brownish lesion (macular about 1cm in diameter) on her left thigh. Lesions gradually became numerous; histologic examination was compatible with Kaposi's sarcoma (KS) and she was referred to our hospital.

She had several brownish-to-reddish nodules spread all over her body, extremities and face and a reddish nodule on the soft palate mucosa. Routine laboratory values and lymphocyte subpopulations were normal and she had a

negative HIV-test, which remained negative for the whole 4-year follow-up period. Antibodies for HBV (Hepatitis B Virus), HCV (Hepatitis C Virus) and EBV (Epstein-Barr Virus) were negative and IgG isotype antibodies to CMV (Cytomegalovirus) were positive (all assayed by ELISA). CT scan revealed borderline (about 1cm in diameter) enlargement of maxillary, mediastinal and retroperitoneal lymph nodes, of questionable clinical significance (location and size of these nodes remained unchanged during the 4-year follow-up). Endoscopic evaluation of the upper GI tract and a barium enema were normal. She received no treatment for KS, but corticosteroid (CS) treatment was stopped after a 45-days tapering period. Four months later skin lesions showed a marked reduction in size and number; oral lesion disappeared.

Six months later she had an exacerbation of SLE with malaise, arthralgias and Coombs-positive anemia. On fundoscopic examination she had bilateral juxtapupillar flameshape hemorrhages. Bone marrow aspirate revealed a severe depression of the erythroid precursors. Anemia did not respond to intravenous immunoglobulins (0.4 g/Kg/day for ten days) and 48 mg methylprednisolone per day were reintroduced. Reticuloerythrocyte ratio, haematocrit and bone marrow aspirate gradually improved. Four months later, she developed a second relapse of multiple brownish lesions suggestive of KS.

Address correspondence to:
Dr. Konstantinos Papazisis, Miaouli 14, Nea Krimi, 55132, Thessaloniki, Greece

The manuscript was received: 15. 11. 2000.

Provisionally accepted: 20. 11. 2000.

Accepted for publication: 22. 11. 2000.



Histologic examination confirmed again the diagnosis of KS. CS dosage was tapered to 4mg methylprednisolone daily (45-days tapering period) and no other treatment was given. Once again the lesions remitted completely.

The patient had two other KS relapses following increase of CS dosage to treat autoimmune haemolytic anemia crises. During her last KS relapse a biopsy was taken again, from a new lesion, revealing an early KS (Figure 1), positive to HHV-8 (Human Herpesvirus-8) by Polymerase Chain Reaction (4) (Figure 2).

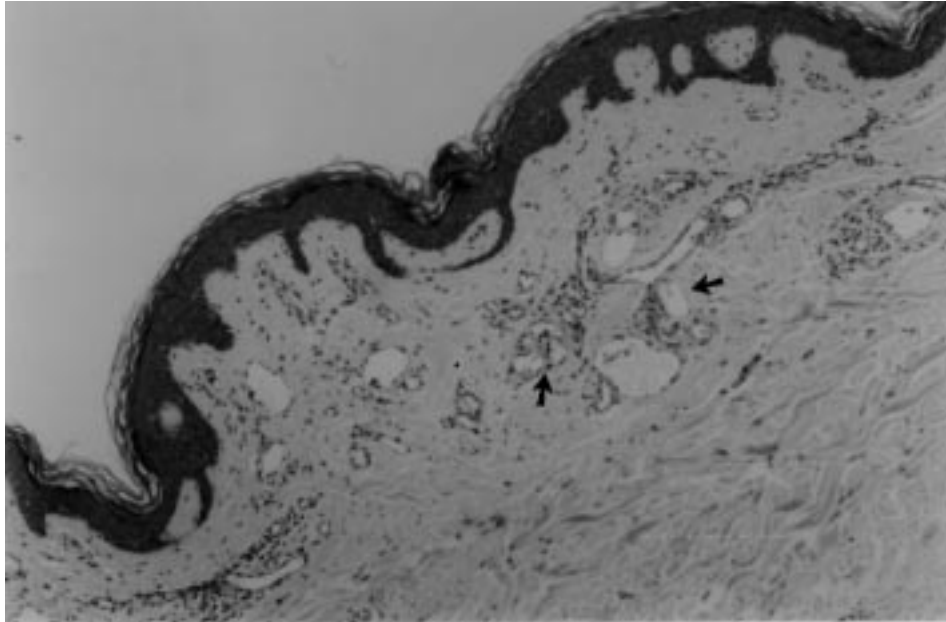


Figure 1. Biopsy material from a patient revealing typical features of Kaposi's sarcoma: atypical ectatic vessels infiltrate the upper dermis, surrounded by lymphocytes and plasma cells (arrows)

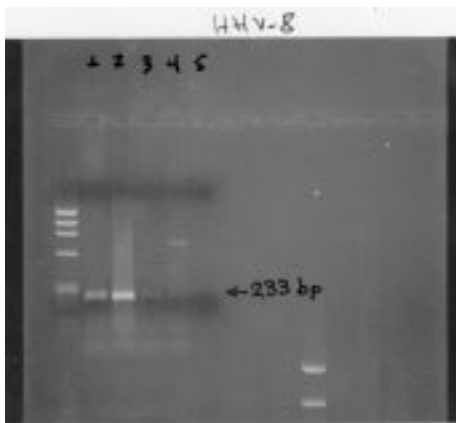


Figure 2. Electrophoresis of the PCR product (using primers against the ORF26 gene of the HHV-8 virus). Lane 1: DNA extracted from the patient's lesion, Lane 2 and 3: DNA extracted from patient's peripheral blood mononuclear cells (200 ng DNA was used for the reaction in lane 3 and 20 ng DNA was used in lane 4), Lane 4: Negative control (HPV-16 positive DNA co-amplified for HHV-8 and HPV-16) and Lane 5: Negative control

Human herpesvirus-8 was also detected in her peripheral blood mononuclear cells

(PBMCs) (Figure 2). KS lesions remitted again following CS dose tapering.

DISCUSSION

Remission of KS after CS-discontinuation has been reported previously in other patients. However, our patient is unique in expressing such an obvious relationship between KS development and CS treatment. Exacerbations and remissions of the Kaposi's sarcoma seem to follow induction and withdrawal of CS treatment

treatment. Second, the dysregulation of host defense mechanisms and cytokine networks in patients with autoimmune disease, can further promote malignant transformation of HHV-8 infected cells (since several cytokines play important role in growth and proliferation of KS cells (9)).

The emergence of KS lesions in a patient with autoimmune disease receiving corticosteroids in the absence of other predisposing factors for the disease (e.g. HIV infection), should be regarded as treatment and/or disease related complication; discontinuation or modification of the immunosuppressive medication should be attempted, since it might result in KS remission. The use of antiviral drugs (10) may also be beneficial.

Acknowledgements

The authors wish to thank Professor H. Moutsopoulos for his helpful discussion and suggestions during the preparation of this manuscript.

REFERENCES

- Buchbinder A, Friedman-Kien AE. Clinical aspects of Kaposi's sarcoma. *Curr Opin Oncol* 1992;4:867-74.
- Klepp O, Dahl O, Stenwig JT. Association of Kaposi's sarcoma and prior immunosuppressive therapy. A 5-year material of Kaposi's sarcoma in Norway. *Cancer* 1978;42:2626-30.
- Casoli P, Tumiatì B. Rheumatoid arthritis, corticosteroid therapy and Kaposi's sarcoma: A coincidence? A case and review of literature. *Clin Rheumatol* 1992;11:432-5.
- Chang Y, Cesarman E, Pessin MS, Lee F et al. Identification of herpesvirus-like DNA sequences in AIDS-associated Kaposi's sarcoma. *Science* 1994;266:1865-9.
- Chang Y. Kaposi's sarcoma and Kaposi's sarcoma-associated herpesvirus (Human herpesvirus 8): Where are we now? *J Natl Cancer Inst* 1997;89:1829-31.
- Boshoff C, Schulz TF, Kennedy MM et al. Kaposi's sarcoma-associated herpesvirus infects endothelial and spindle cells. *Nature Med* 1995;1:1274-8.
- O'Leary JJ, Kennedy MM, McGee J O'D. Kaposi's sarcoma associated herpes virus (KSHV/HHV 8): epidemiology, molecular biology and tissue distribution. *J Clin Pathol Mol Pathol* 1997;50:4-8.
- Hundall SD, Rady PL, Tying SK, Fish JC. Hydrocortisone activation of human herpesvirus 8 viral DNA replication and gene expression *in vitro*. *Transplantation* 1999;67:648-52.
- Miles SA, Rezaei AR, Salazar-Gonzales JF et al. AIDS Kaposi sarcoma-derived cells produce and respond to interleukin 6. *Proc Natl Acad Sci USA* 1990;87:4068-72.
- Morfeldt L, Torssander J. Long term remission of Kaposi's sarcoma following Foscarnet treatment. *Scand J Infect Dis* 1994;26:749-52.