



Nikola BUDIŠIN
Ivan MAJDEVAC
Milan BREBERINA
Branimir GUDURIĆ

Total gastrectomy and its early postoperative complications in gastric cancer

ABSTRACT

Background: The study shows operative results and complications occurring in the first 30 days after total gastrectomy because of stomach cancer.

Materials and methods: Retrograde analysis was performed using medical documentation and histologic findings of 76 patients after total gastrectomy done between 1990 and 1997. Mortality and postoperative complications were analysed. Complications were sorted as specific and non-specific. All operations were done either for intestinal gastric cancer located in proximal stomach or for diffuse stomach cancer. All anastomoses were sewn by hand. Eight surgeons were performing the operations.

Results: There were 43 male and 33 female patients. Postoperative mortality was 14.4%. Most frequent complications were: dehiscence of oesophago-jejuno anastomosis, which happened in 15.8% of operated patients, postoperative temperature without apparent infection in 5.2%, thrombophlebitis in 5.2%. Pneumothorax with a frequency of 3.9%, hepatic necrosis in one patient 1.3%, and perforation of jejunal loop with nasogastric tube in 1.3%, which all ended fatally contributed to the relatively high mortality. Mean postoperative intrahospital treatment lasted 12.3 days. Dehiscence of oesophagoentero-anastomosis, resulted in generalised peritonitis in 66.6%. Six patients succumbed as a consequence, while two survived with subphrenic and intraansal abscesses. Pneumothorax in combination with total gastrectomy was always fatal.

Conclusion: Routine use of stapling surgery, sub-specialisation in surgery and better early intensive care monitoring and treatment could improve mortality rate.

Key words: Gastric cancer; Surgery; Resection; Gastrectomy; Complications

DEPARTMENT OF SURGERY, INSTITUTE OF ONCOLOGY
SREMSKA KAMENICA, SREMSKA KAMENICA, YUGOSLAVIA

Archive of Oncology 2000,8(3):91-4©2000, Institute of Oncology Sremska Kamenica, Yugoslavia

INTRODUCTION

The incidence of gastric cancer is declining in the west, as well as in Vojvodina and Yugoslavia (1). However, it seems, that decline is due to the drop of incidence of the intestinal type of gastric cancer. On the contrary, incidence of the diffuse type of cancer is increasing or at least remaining the same. The incidence of the gastric cancers located proximally in stomach is increasing (2). Principal intention of the operation for gastric cancer is to remove the tumor, to secure healthy edges of resection and to restorate the digestive tube. Potential multilocularity of tumor (3), submucosal spreading away from visible edge of tumor as well as attempts to

secure healthy proximal resection line, engage total gastrectomy in the treatment of tumors, even located distally. Once associated with high mortality, it is today standard operation for cancer treatment, equally important as subtotal resection.

At the Institute of Oncology Sremska Kamenica, Novi Sad, the largest hospital for treating the malignancies in the province of Vojvodina, which is the northern province of Yugoslavia with 2013890 inhabitants according to the 1991 census, total gastrectomy was seldom performed before 1990. The first operation was done in 1986, followed by four other operations till 1990, performed by two surgeons, with mortality of 40%. Since the beginning of 1990, after adopting a new approach of operative treatment which engaged different treatment of two different histologic types of gastric cancer after Lauren's classification (4), and appearance after Borrmann (5), we had 76 operations during the period from the 1st of January 1990 till the 1st of June 1997. The operations were conducted by eight surgeons without stapling devices. The complications and mortality of the procedure are reviewed accentuating having been put on the postoperative complications which ended fatally.

MATERIALS AND METHODS

Retrograde study using medical documentation and histologic findings covers the period commencing on 1st of January 1990 and ending on 30th of June 1997. Patients, included in the study, were the patients with histologic evidence of gastric cancer, who due to the type or location of the tumor were submitted to total gastrectomy (TG) at the Institute of Oncology in Sremska Kamenica. The operation was performed in 76 cases. There was no exclusion of the operated patients. No statistic analysis was employed.

Indications for total gastrectomy were: any location of gastric carcinoma of Borrmann 4 type or of diffuse type of gastric cancer. Intestinal and mixtus types of gastric cancer of Borrmann 3 type when situated in proximal 5 cm of stomach and intestinal and mixtus types of gastric cancer of Borrmann 1 or 2 type when placed in proximal 2 cm of stomach. Resection was abandoned in cases of: anesthesiologic contraindications, massive distant metastases, carcinosis of peritoneum and ascit; and in patients whose

Address correspondence to: Prim. Dr Nikola Budišin,
Department of Surgery, Institute of Oncology Sremska
Kamenica, 21204 Sremska Kamenica, Institutski put 4,
Yugoslavia

The manuscript was received: 04. 04. 2000.

Provisionally accepted: 19. 04. 2000.

Accepted for publication: 15. 05. 2000.



performance status was 30% or less, using Karnofsky (6) index. Patients with preoperatively diagnosed involved distal esophagus were transferred to Department of Thoracic Surgery at the Institute for chest diseases for further treatment and were not included in this study.

Mortality was defined as the lethal outcome during the operation and first thirty postoperative days. Complications have also been calculated if aroused in the same period. Complications that have led to lethality were separately described and discussed.

Patients were admitted at the Department of Surgery with known diagnosis, positive histologic findings after gastroscopy, with description of tumor after Borrmann. Their histologic findings included Laurens subdivision on diffuse, intestinal or mixtus type of gastric cancer. Routine laboratory findings, blood group, blood sample, urinalysis, chest X-ray, EKG, ultrasonography of liver and in female patients gynecological findings were also required. Histology of resected specimens used TNM system while stages were determined by United international gastric cancer staging classification system (7).

The operations were conducted in general anaesthesia through abdominal approach. Each operation included at least gastrectomy, extirpation of both omentums, accompanied with lymphadenectomy either D1 or D2. In case of perigastric spread of the disease combined resection was employed, with removal of adjacent organs or part of organs. Reconstruction oesophagojejunostomy was performed in three different manners, namely via Omega loop of jejunum, by the means of roux loop, and/or interposition of jejunal loop without separation from continuity of intestine - known as Tomoda's method. Method of reconstruction depended on preference of the operating surgeon. There were eight surgeons performing the operations, none of who used only one method of reconstruction. All anastomoses were hand sewn. Postoperatively, until the peristaltic waves, patients were attended by the personnel of the intensive care unit.

RESULTS

Total gastrectomy was performed in 76 cases. There were 43 males and 33 female patients, aged between 28 and 73 years, mean age having been 54.6 years. Both male and female ratio was 1.3. Postoperative histology showed that there were 5 early gastric carcinomas (7% of cancers), and 66 advanced cancers (93%). Fifteen out of these were of intestinal type, 49 of diffuse type and 8 of mixed type. Remaining four cases remained unspecified. Thirty three of patients presented with infiltration of tumor to the surrounding structures - T4 tumor, followed by 19 patients with tumor invading serosa - T3, 12 patients of tumor infiltrating gastric wall but not serosa - T2, and 8 cases of T1. Majority of patients had positive N2 lymph nodes, 31 patient, 25 patients had positive

only N1 lymph nodes, while 16 patients had negative lymph nodes. Seventy patients were without metastasis while 6 had them. Ten patients were in Stage I of the disease, 9 in stage II, 22 in stage III and 31 in stage IV. In four cases stage was not determined, due to the incomplete histology.

Reconstruction included esophagojejunostomy via Roux en Y loop in 41 case, after Tomoda's method in 31 cases and using Omega loop in 4 cases. Forty two cases were accompanied by D2 lymphadenectomy while 34 patients underwent D1. All anastomoses were hand sewn. Extended resections were performed in 21 cases, 4 patients with resection of the colon and 17 patients with splenectomy and dissection of splenic port with distal pancreatectomy. Positive lymph nodes in splenic port, verified by histology, were found in just one case out of 17 cases after the splenectomies (5.8%).

Table 1. Main clinical, pathological and surgical variables in patients undergoing total gastrectomy

Characteristics	n (%)
Number of patients	76
Male	43 (56.6)
Female	33 (43.4)
M/F ratio	1.3
Age	28-73
Mean age	54.6
Median age	57
Invasion of gastric wall p T	
pT1	8 (10.5)
pT2	12 (15.8)
pT3	19 (25.0)
pT4	33 (43.4)
Not assessed	4 (5.3)
Nodal status	
N0	16 (21.0)
N1	25 (32.9)
N2	31 (40.7)
Not assessed	4 (5.3)
Distant metastasis	
M0	70 (92.1)
M1	6 (7.9)
Stage of disease	
Stage Ia	5 (6.6)
Stage Ib	5 (6.6)
Stage II	9 (11.8)
Stage IIIa	10 (13.1)
Stage IIIb	12 (15.8)
Stage IV	31 (40.8)
Unspecified	4 (5.3)
Histologic type	
Intestine	15 (19.7)
Diffuse	49 (64.5)
Mixtus	8 (10.5)
Unspecified	4 (5.3)
Type of esophagojejunostomy	
Roux en Y	41 (53.9)
Tomoda	31 (40.8)
Omega	4 (5.3)
Extent of lymphadenectomy	
D1	34 (44.7)
D2	42 (55.3)
Extended resections	21 (27.6)
Splenectomy & dist. Pancreatectomy	17 (22.3)
Resection of colon	4 (5.3)

There were eleven postoperative lethal outcomes, which gives overall mortality of 14.4%. Mean intrahospital treatment lasted 17.29; posoperatively 12.28 days (range from 2 to 43 days, SD = 5.76).

Complications

Complications were calculated for the first 30 postoperative days, during the intrahospital postoperative period. They were regarded either as specific complications, which resulted as the consequence of gastric operation - total gastrectomy, or nonspecific, common after any surgery. All nonspecific complications were treated as expected, except pneumothorax where drainage of thoracic cage was employed in addition of intensive care measures.

Table 2. Nonspecific early postgastrectomy complications, incidence and mortality

Nonspecific complications	No. of pts.	Incidence (%)	Fatal outcome (%)
Thrombophlebitis	4	5.3	0
Temperature without apparent cause	4	5.3	0
Pneumothorax	3	3.9	100
Pneumonia	3	3.9	0
Wound infection	3	3.9	0

Table 3. Specific early postgastrectomy complications, incidence and mortality

Specific complications	No. of pts.	Incidence (%)	Fatal outcome (%)
Dehiscence of oesophagojejunostomy	12	15.8	50
Pancreatic fistula	2	2.6	0
Hepatic necrosis	1	1.3	100
Perforation of intestine with nasogastric tube	1	1.3	100

Pancreatic fistulas were also treated conservatively, as well as the case of hepatic necrosis and some of the cases of dehiscence of oesophagojejunal anastomosis, while all recognized cases of peritonitis were treated by reoperations.

Complications which ended lethally

The most frequent complication after the resection was dehiscence of oesophagojejunostomy. It occurred in 12 patients (15.8) some of them were recognized with routine peroral contrast given on the 4th postoperative day, while the others, presented with clear clinical manifestations, were confirmed by the x-ray. Four out of these twelve cases (33.3%) were minor leaks, clinically silent, accompanied only with prolonged absence of peristaltic waves, and slightly raised pulse in one patient. Prolonged nasogastric suction, intravenous fluids, antibiotics, total parenteral nutrition and careful intensive monitoring, was the manner of treatment in these patients. All four patients recuperated completely. Eight other patients (66.6%) developed generalized peritonitis, six of which succumbed to the illness. Remaining two patients survived, one after the conservative therapy, with local

ized subphrenic abscesses as a consequence, the other after the reoperation. Since all patients had abdominal drains inserted at the conclusion of operation, quantity of drain content was crucial for the decision for further treatment. Dehiscence was treated conservatively if drain content was less than 500 ml daily, or reoperated if it was more. Conservative treatment included insertion of central venous line, control of the acidbase, fluid and electrolyte balance, antibiotics, cardiotonics in elderly and total parenteral nutrition. At the reoperation overswinging of leakage or resture of the anastomosis was done. However these attempts resulted in poor effect. Five out of six patients who succumbed were reoperated, while one was conservatively treated. Overall mortality for this complication including leaks was 50%, it was 75% for major desiscences, while mortality for reoperated patients reached 83.3%. Major leaks, treated conservatively, had mortality of 50%, while all minor ones survived.

Pneumothorax. Two cases resulted with the insertion of subclavian catheter at the conclusion of the operation. The third one arouses from rupture of emphysematous bulla during the operation. Increased resistence to ventilation accompanied by hypoxia, tachycardia and drop of arterial tension was observed in this case. Diagnosis was made in recovery room after the x-ray was taken, few hours after the operation. Although all three cases were recognized early and promptly treated with underwater sealed drainage, all three patients succumbed.

Reexpansion of the lung occurred partially just in one case while two remaining patients died without it. Airways plugged with mucus combined with weakened respiratory effort could have contributed to failed reexpansion. Cardio-respiratory insufficiency without any traces of dehiscence of the anastomosis was indicated as the cause of demise at autopsy. Atelectasis combined with pneumothorax was evident in one case.

Hepatic necrosis resulted from unintentional ligation of abberant common hepatic artery. Patient presented with jaundice on the third postoperative day, elevated serum transaminase levels, leukocitosis, fever combined with abdominal pain, hepatomegaly and prolonged lacking of peristalsis. This was understood as postoperative toxic hepatitis. No surgical reoperation was attempted, patient remained in intensive unit and was treated conservatively. Complication ended with demise on the 9th postoperative day. Common hepatic artery was found ligated, on autopsy which aroused from left gastric artery. Artery was not recognized in the course of operation, due to the enlarged and melted lymph nodes around celiac trunk.

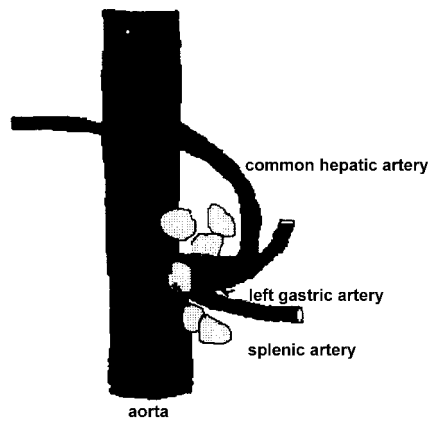


Figure 1. Ligature tied around common arousal of left gastric artery and common hepatic artery

Perforation of jejunal loop with nasogastric tube showed up on the fifth postoperative day with the signs of generalized peritonitis. Metabolic acidosis accompanied with tachycardia, localized tenderness of abdomen and lack of peristaltic waves. Content of abdominal drain bag, was not conclusive. Nasogastric suction, which was put in place during the operation with the tip of the tube in jejunal loop, and since installation, was left undisturbed, showed diminished volume in the last 24 hours prior to clinical signs. Intermittent negative pressure through nasogastric tube, was employed during the four days preceding the perforation, with intermittent negative pressure of 10 mm of water column applied, 2 hours on followed by two hors off. Nasogastric tube was neither moved nor rotated in, the postoperative period. Contrast peroral radiography showed spilling of contrast in abdominal cavity. Patient was submitted to reoperation with suspected dehiscence of esophagojejuno anastomosis.

Intraoperative finding showed anastomosis without dehiscence, as well as properly closed duodenum. Drain was occluded with fibrin and did not function. Peritoneal cavum was soiled with intestinal content. The perforation on intact efferent jejunal loop was found 15 cm from anastomosis with esophagus, with nasogastric, elastic tube protruding through intestine in abdominal cavity.

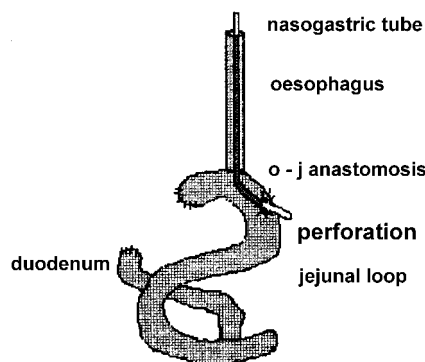


Figure 2. Perforation of jejunom with the tip of the nasogastric tube

During the reoperation, the abdomen was washed out, perforation on the intestine was oversued, abdomen drained. Intensive antibiotic therapy combined with correction of acidosis, and hypovolemia followed in recovery room. Despite these measures, patient did not recover. Septic shock was ascribed as cause of death. No abnormality was found in the structure of intestine wall regarding anatomy or histology, on autopsy.

DISCUSSION

Most of the authors advocated combined resection of spleen and distal pancreas in proximally sited gastric cancer with TG, in order to achieve better clearance of lymph nodes in splenic hilus. On the other hand, there is an increasing number of recent studies that doubt this approach, having in mind survival, morbidity, mortality and postoperative quality of life (8-11). In our seventeen cases with splenectomy and distal pancretectomy done, we had two cases of postoperative pancreatic fistulas (11.8%), which considerably prolonged hospital stay, while the incidence of positive histologic lymph nodes in splenic hilus was only 5.9%. This changed our policy toward the extension of operation, which was serially done for proximal sited cancers during the first two years, to apply it later, just in cases when tumor is situated proximally and had a palpable lymph nodes in splenic hilus, or directly invaded or was adherent with spleen.

Anatomic anomaly regarding origin of common hepatic artery from the left gastric artery occurs in less than 1% of population (12). Few authors dealt with arterial aberrations and postgastrectomy complications. Most of them (13,14) advise preoperative angiography to exclude this malformation. Procedures of reconstruction of hepatic artery during gastric resection were described (15). In our operation, which was conducted without preoperative angiography and which included D2 lymphadenectomy with extirpation of lesser omentum under hemostats, with enormously enlarged lymph nodes, the anomaly remained unrecognized. Angiography as the routine preoperative finding is unfortunately unaffordable in Yugoslavia, bearing in mind the costs of the procedure, prolongation of the intrahospital stay and the possibility of misinterpretation of the findings.

Perforation of the jejunal loop, away from suture line on intact intestine led us to change the approach to the postoperative nasogastric tube. Before the incident, the tube was regarded as the stent as well as the decompression device, which was connected to the intermittent negative pressure. Once installed, during the operation, it was neither moved, nor touched for at



least four postoperative days, until control radiography. After this complication, we accepted the policy of passive suction with the irrigation of the tube with 20 ccm of saline twice a day combined with mild rotation. This, we believe, reduces the pressure on the same point, and precludes the aspiration and sticking of the intestinal mucosa which could arise possible ishaemia.

We did not find connection in literature between perioperatively aroused pneumothorax and total gastrectomy. Most of the literature deals with preoperatively diagnosed respiratory diseases and their influence on mortality. There are authors who suggest that preoperative peak expiratory flow rate, in elderly patients (16) and preoperative Pa, O₂ are significant findings in preclusion of postoperative pulmonary complications. These are not usual preoperative findings in our hospital. Preoperatively diagnosed respiratory disease was reported to increase morbidity (17,18). In our experience, only one case out of three had preoperative pulmonary disease - emphysema. Two other cases were connected with the installation of subclavian venous catheter, done in general anesthesia at the conclusion of the operation. Since this is not an unusual medical intervention, it is curious that no other similar accidents have been reported. All three patients succumbed contributing to the mortality of this complication 100% in our experience.

CONCLUSION

In the last two decades Japanese authors have put new frontiers regarding resectability, and survival in the treatment of gastric cancer. Mortality has dropped after TGtg to less than 2% in Japan, but remained between 8-20% in various West European, American and South African clinics with tendency of further declining. Mortality could be reduced with the experience, and in subspecialised clinics as has already been reported (19). It should be said, that there is no particular person regarding surgeons, anesthesiologists or pathologists dealing only with gastric cancer in Vojvodina. We have managed to decrease mortality from 40% at the start of performing this procedure to acceptable 14.6%, 1990 being the breaking point. An increased number of operations have contributed to this, as well as introduction of new generation of surgeons.

Two unusual surgical complications, perforation of jejunal loop and hepatic necrosis, have thought us the lesson to be more careful in the intensive care unit with the nasogastric tube as well as to be aware of possible vascular aberrations. Connection between intraoperative pneumothorax and total gastrectomy, concerning high mortality, deserves further investigation.

With better preoperative diagnostics, that

would include barium meal, endoscopic ultrasound, CT regarding the staging of tumor, and better preoperative pulmonary evaluation, as well as with better intraoperative and postoperative monitoring and care, we could further on decrease mortality after total gastrectomy. Intraoperative improvements combined with selection of operating team, and introducing stapling surgery, would certainly lead to better survival.

REFERENCES

1. Mikov MM, Burany B, Zdravković S. Epidemiological characteristics of gastric cancer in Vojvodina. *Eur J Epidemiol* 1997;13:523-5.
2. Parkin DM, Pisani P, Ferlay J. Estimates of the worldwide incidence of 25 major cancers in 1990. *Int J Cancer* 1999;80:827-41.
3. Collins WT, Gall EA. Gastric carcinoma, multicentric lesion. *Cancer* 1952;5:62-72.
4. Lauren P. The two histologic main types of gastric carcinoma: diffuse and so called intestinal type carcinoma. *Acta Pathol Microbiol Scand* 1965;64:31-49.
5. Borrmann R. Geschwulste des Magens. In: Henke FU, Lubars O, eds. *Handbuch der Speziellen Pathologischen Anatomie und Histologie IV, erster Teil*. Berlin: Springer-Verlag, 1926:864-71.
6. Karnofsky DA, Burchenal JH. The clinical evaluation of chemotherapeutic agents in cancer. In: *Evaluation of Chemotherapeutic Agents; symposium, microbiology section*. New York: Columbia University Press, 1949.
7. Kennedy BJ. The united International Gastric Cancer Staging Classification System. *Scand J Gastroenterol* 1987;22(suppl.133):11-3.
8. Brady MS, Rogatko A, Dent LL, Shiu MH. Effect of splenectomy on morbidity and survival following curative gastrectomy for carcinoma. *Arch Surg* 1991;126:356-64.
9. Wanebo HJ, Kennedy BJ, Winchester DP, Stewart AK, Fremgen AM. Role of splenectomy in gastric cancer surgery: adverse effect of elective splenectomy on longterm survival. *J Am Coll Surg* 1997;185:177-84.
10. Otsuji E, Yamaguchi T, Sawai K, Ohara M, Takahashi T. End results of simultaneous splenectomy in patients undergoing total gastrectomy for gastric carcinoma. *Surgery* 1996;120:40-4.
11. Roukos DH. Current advances and changes in treatment strategy may improve survival and quality of life in patients with potentially curable gastric cancer. *Ann Surg Oncol* 1999;6:46-56.
12. Lippert H, Pabst R. Hepatic arteries. In: *Arterial variation in man, classification and frequency*. Munchen: JF Bergmann Verlag, 1985:32-33.
13. Okano S, Sawai K, Taniguchi K, Takahashi K. Aberrant left hepatic artery arising from the left gastric artery and liver function after radical gastrectomy for gastric cancer. *World J Surg* 1993;17:70-4.
14. Hemming AW, Finley RJ, Evans KG, Nelems B, Fradet G. Esophagogastrectomy and the variant left hepatic artery. *Ann Thorac Surg* 1992;54:166-8.
15. Takenaka H, Iwase K, Ohshima S, Hiranaka T. A new technique for the resection of gastric cancer: modified Appleby procedure with reconstruction of hepatic artery. *World J Surg* 1992;16:947-51.
16. Fan ST, Lau WY, Yip WC, Poon GP, Yeung C, Lam WK, et al. Prediction of postoperative pulmonary complications in

oesophagogastric cancer surgery. *Br J Surg* 1987;74:408-10.

17. Wu CW, Hsieh MC, Lo SS, Wang LS, Hsu WH, Lui WY, et al. Morbidity and mortality after radical gastrectomy for patients with carcinoma of the stomach. *J Am Coll Surg* 1995;181:26-32.

18. Frey P. Respiratorische Insuffizienz und Operabilität. *Schweiz Med Wochenschr* 1979;109:1562-4.

19. Dent DM, Madden MV, Price SK. Randomised comparison of R1 and R2 gastrectomy for gastric carcinoma. *Br J Surg* 1988;75:110-2.