

# Melanoma metastatic to the breast: a report of an unusual case

Nataša Prvulović, Dragana Đilas-Ivanović, Borislava Nikolin, Bratislav Stojiljković

**Key words:** *Melanoma; Neoplasm Metastasis, Breast Neoplasms*

Breast metastases are rare, dominantly arising from contralateral breast. Based on the literature, an incidence of 1.2% to 2% is reported for extra-mammary origin of breast metastases (1). Malignant melanoma, pulmonary carcinoma, and Non-Hodgkin lymphoma are tumors that more frequently spread to the breast. Usually, at the time of presentation in the breast, metastatic nodules are also seen in subcutaneous tissue on extremities or chest-abdominal wall with or without parenchymal organs involvement. Several studies show that the time from diagnosis of primary melanoma and the occurrence of breast metastasis ranged from 2 to 9 years, while the survival time from metastasis to the breast to death ranged from 2 to 10 months (2). Melanoma metastasis to the breast can be presented as solitary breast lump or as multiple and bilateral masses, which can be palpable or not, depending of their size and location. Opposite to the primary breast cancers nipple changes, skin involvement, or retractions are not presented in metastatic breast tumors. Radiological presentation are usually, just like other metastases, rounded and well defined, benign in appearance, but it should be suspected as metastatic disease in all patients with a prior history of malignant neoplasm (3).

A 53-year-old patient was operated for small, pigmented tumor on her left foot. The results of histopathology analysis reported superficially spreading type of melanoma cutis, Breslow II (12 mm), Clark IV. After two years, a metastatic lymph node of 21 x 11 mm in diameter was resected from left groin. Disease progressed quickly and subcutaneous nodes appeared on anterior abdominal wall and right upper arm. Two nodes were excised from the skin of upper arm. Histopathological lymph node analysis shows large epithelioid cells with anisocytosis and anisonucleosis with prominent eosinophilic nucleoli and pathological mitosis (Figure 1).

The results of CT and ultrasonographic examinations of the abdomen showed no secondary lesions in parenchymal organs; however, abdominal subcutaneous nodules and enlarged lymph nodes in axillas were present. Ultrasound examination of breast showed multiple ovals, clearly margined, 7 mm in diameter, and hypoechoic lesions with posterior acoustic enhancement, dominantly subcutaneous and located in both breasts (Figure 2). The results of mammography showed metastases also presented as multiple masses with circumscribed borders in left and right breast (Figure 3).

*Arch Oncol* 2011;19(3-4):79-80.

UDC: 618.19-006:616-006.8:616.072  
DOI: 10.2298/A001104079P

Oncology Institute of Vojvodina,  
Sremska Kamenica, Serbia

Correspondence to:  
Dr. Nataša Prvulović,  
Oncology Institute of Vojvodina,  
Instituski put 4,  
21204 Sremska Kamenica  
[prvulovicn@gmail.com](mailto:prvulovicn@gmail.com)

Received: 09.11.2011  
Provisionally accepted: 01.12.2011  
Accepted: 07.12.2011

© 2011, Oncology Institute  
of Vojvodina, Sremska Kamenica

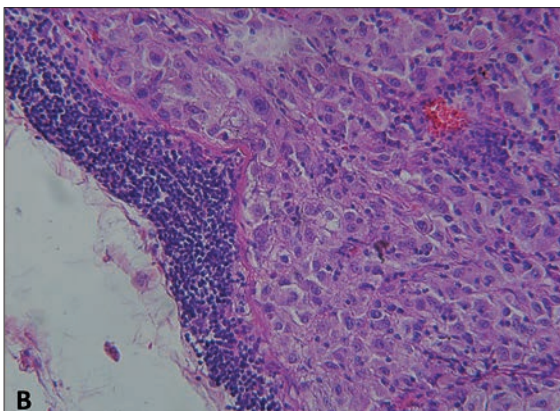
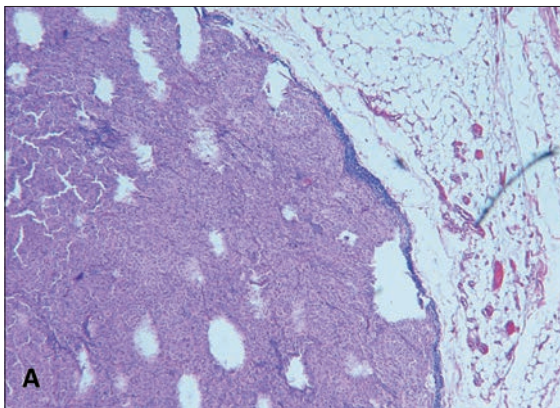


Figure 1. (A) Malignant melanoma metastatic to lymph node, (H&E stain, x250); (B) Preserved lymph tissue alongside the capsule of the node and epithelioid melanoma cells shown at the right side (H&E stain, x500)

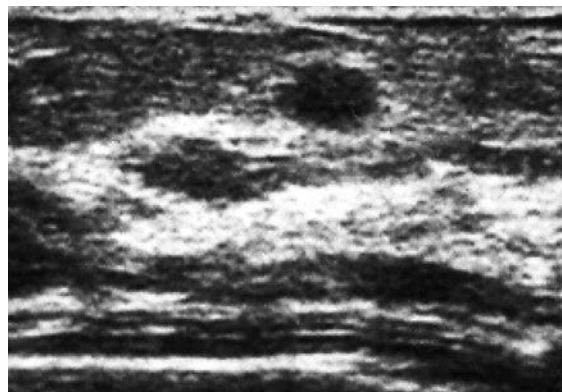


Figure 2. Breast ultrasound shows oval clearly demarcated hypoechoic node with slightly acoustic enhancement

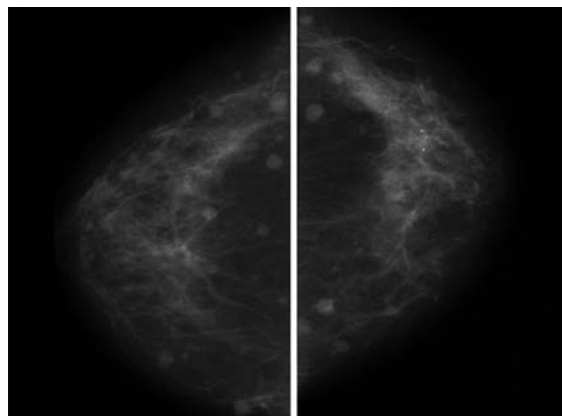
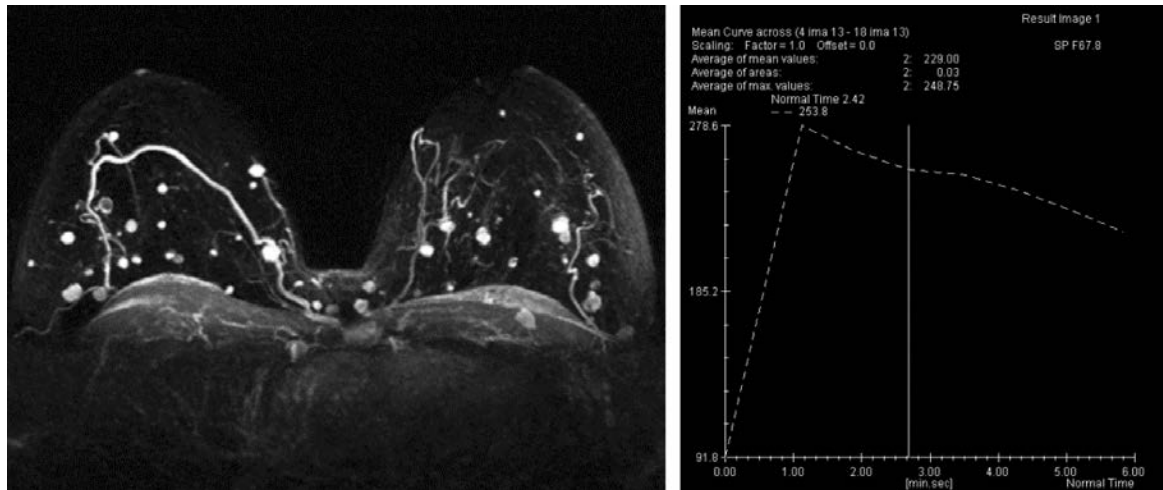


Figure 3. Bilateral mammograms in CC plane show numerous circumscribed round masses in both breast



**Figure 4.** Magnetic resonance MIP image and post contrast time-intensity curve show many oval post contrast enhanced lesions dominantly subcutaneous located in both breast and in mediastinal wall. Time intensity curve demonstrate typical pathologic initial enhancement with rapid wash-out

MR imaging was performed at 1.5T scanner, in T2W and FLASH 3D dynamic postcontrast sequences. The results of breast MR examination showed the presence of secondary deposits subcutaneously in both breasts, axillas, and in the segment of anterior thoracic wall. On T2W images, they are presented as low signal intensity masses, intermediate SI on T1W images with pathological, dominantly periphery-rim postcontrast enhancement (Figure 4).

As there was no evidence of metastatic changes of internal organs the patient was treated with four series of DTIC/CDPP protocol therapy in four weeks intervals. The patient died eight months after the diagnosis of breast metastases.

## DISCUSSION

Breast involvement in malignant melanoma is not an isolated finding; it is usually associated with disseminated disease. Subcutaneous tissue, lung, liver, and brain are common secondary involvements in this disease. Breast metastases are poor prognostic sign (4).

Shetty et al. (5) reported a review of literature, presenting data from 1855 to 1992, and found 431 cases of secondary extra-mammary breast tumors. The most of them represents metastases from malignant melanoma (79 cases), followed by lung cancer metastases (78 cases), ovary cancer (50 cases), prostate (39 cases), kidney (24 cases), and other (143 cases).

It is mandatory to differentiate primary from secondary tumor because the treatment of these two malignancies differs. In patient with solitary breast metastasis (confirmed by core biopsy) breast conserving therapy can be performed, opposite to multiple metastases in single or both breasts where systemic chemotherapy is indicated.

Diagnosis of metastatic breast disease involves the work of a multidisciplinary team of specialists. A radiologist should perform all imaging necessary for establishing an optimal diagnosis. Fine needle aspiration biopsy or core needle biopsy are done to obtain histopathological diagnosis. Oncologists, surgeons, pathologists, and radiologists have to work together to reach the best possible therapy against this aggressive type of cancer.

## Conflict of interest

We declare no conflicts of interest.

## REFERENCES

- 1 Maounis N, Chorty M, Legaki S, Ellina E, Emmanouilidion A, Demonakon M, et al. Metastases to the breast from an adenocarcinoma of the lung with extensive micropapillary component : A case report and review of the literature. *Diagn Pathol.* 2010;5:80.
- 2 Ravdel L, Robinson WA. Metastatic melanoma in the breast: A report of 27 cases. *J Surg Oncol.* 2006;94:101-4.
- 3 Noguera JJ, Martinez-Miravete P, Idoate F, Diaz L, Pina L, Zoruoza G, et al. Metastases to the breast: A review of 33 cases. *Australas Radiol.* 2007;51(2):133-8.
- 4 Williams SA, Eklers RA, Hunt KK, Singletary SE, Ross MI, Symmas WF, et al. Metastases to the breast from nonbreast solid neoplasms : Presentation and determination of survival. *Cancer.* 2007;110:731-7.
- 5 Shetty MR, Ahmed MI, Khan FR. Metastatic tumors to the breast: a review: 1855 AD to 1993 AD. In: *Proceedings of the XVI UICC International Cancer Congress.* New Delhi, India, Bologna, Italy: Monduzzi Editore; 1994. p. 1577-81.