

Rare complication of chemotherapy in testicular cancer

Ehab Helmy Abdel Goad

SUMMARY

Testicular neoplasms metastasizing to the retroperitoneum rarely involve the upper gastrointestinal tract. We describe an unusual case of contained small bowel perforation as a complication of chemotherapy treatment of metastatic non seminomatous germ cell cancer in a 32-year-old man.

Key Words: Testicular Neoplasms; Neoplasms, Germ Cell and Embryonal; Neoplasm Metastasis; Retroperitoneal Neoplasms

CASE REPORT

A 32-year-old man was referred to oncology clinic with history of loss of weight, intractable headache, and right scrotal mass for which he had radical orchidectomy.

The histology of his testes showed mixed germ cell tumor with predominant embryonal carcinoma, lymphovascular involvement, and extension of the tumor through the tunica albuginea.

The patient was severely wasted with large firm non tender abdominal mass. We did not have a record of his preorchidectomy tumor markers however his alpha fetoprotein, HCG and LDH were markedly elevated on presentation to our clinic.

CT scan of the chest, abdomen, and pelvis revealed multiple lung nodules and large solid abdominal mass with displacement of the major vessels and hydronephrosis (Figure 1).

The MRI of the brain revealed cerebral metastases with hydrocephalus for which he had cerebroperitoneal shunt (Figure 2).

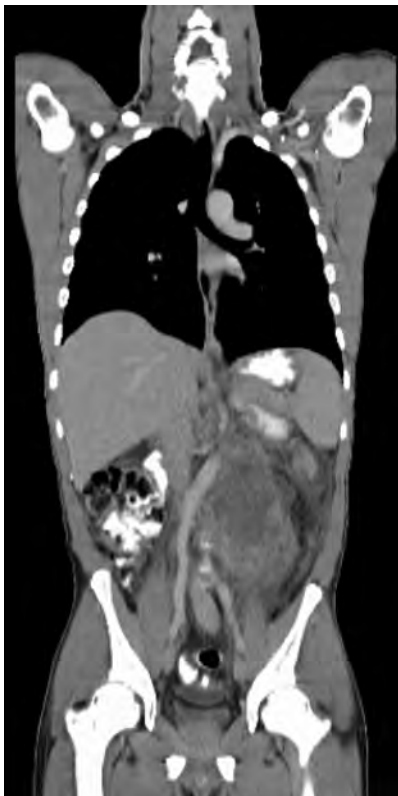

Figure 1. Large solid mass displacing the bowel, aorta, and IVC to the right

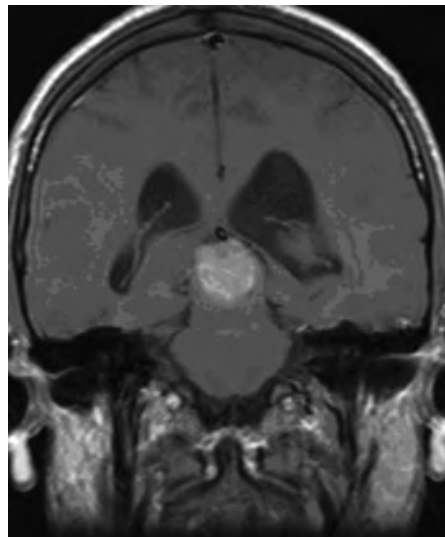


Figure 2. MRI shows cerebral mass with hydrocephalus

The patient subsequently received 4 cycles of bleomycin, etoposide, and cisplatin with radiotherapy to the brain.

Post completion of the treatment his tumor markers were within the normal level and his brain MRI revealed complete resolution of the cerebral mass.

His chest CT scan was normal however his abdominal CT scan showed incomplete resolution of the abdominal mass with fluid and air level (Figure 3).

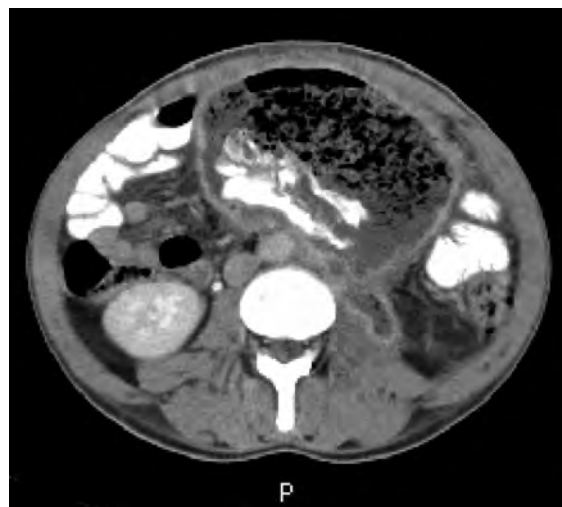

Figure 3. CT abdomen shows air fluid level with contrast in the abdominal mass with areas of solid component

Arch Oncol 2009;17(1-2):25-6.

UDC: 616.681-006.615.38:616-06

DOI: 10.2298/AOO0902025G

Clinical Head of Department of Urology,
E Thekwini District, Kwa Zulu Natal,
South Africa

Correspondence to:

Dr EH Abdel Goad, 21 Chancellor
Avenue, 8 Amarillo, Berea 4001,
Durban, South Africa

abdelgoad@hotmail.com

Received: 16.03.2009

Provisionally accepted: 10.04.2009

Accepted: 14.04. 2009

© 2009, Oncology Institute of
Vojvodina, Sremska Kamenica

On exploratory laparotomy a large thick wall mass was encountered arising from the left paraortic lymph nodes with adhesion to the small bowel.

On careful dissection a small bowel perforation was draining to the mass with small bowel content filling the partially necrotic lymph node.

The mass was removed and the bowel was resected and the continuation of the small bowel was reestablished with end to end anastomosis.

The pathological examination showed fibrotic lymph nodes with chronic inflammatory wall and no evidence of malignancy in the wall or the small bowel.

The patient recovered well and shows no evidence of recurrence 3 years post laparotomy.

DISCUSSION

Involvement of the GI tract by metastatic testicular cancer is rare. Fewer than 5% of patients with metastatic testicular cancer present with gastrointestinal involvement

Few reported cases of bowel involvement with germ cell tumor and most of the reported cases are due to metastatic germ cell cancer to the bowel (1-6). The chemotherapy treatment can result in fibrosis of the retroperitoneal metastatic lymph nodes with persistent radiological changes with normalization of the tumor markers.

Surgical excision of the large retroperitoneal mass can exclude metastases and spare the patient unnecessary second line chemotherapy.

In our patient there was no evidence of involvement of the bowel with germ cell tumor on the initial presentation and post resection of the mass did not show any malignant involvement of the bowel.

As far as we know there is no reported case of bowel perforation as a complication of the chemotherapeutic treatment of the germ cell tumor.

However the possibility that there was tumor involvement of the small bowel with complete resolution on chemotherapy treatment cannot be excluded.

Conflict of interest

We declare no conflicts of interest.

REFERENCES

- 1 Brown RS, Yassin J, Hayne D, Colville C, Harland SJ, Payne HA. First report of an isolated jejunal seminoma: presentation with melaena and iron deficiency anemia. *Clin Oncol (R Coll Radiol)*. 2001;13(6):455-7.
- 2 Sweetenham JW, Whitehouse JM, Williams CJ, Mead GM. Involvement of the gastrointestinal tract by metastases from germ cell tumors of the testis. *Cancer*. 1988;61:2566-70.
- 3 Chait MM, Kurtz RC, Hajdu SI. Gastrointestinal tract metastases in patients with germ cell tumor of the testis. *Dig Dis*. 1978;23:925-8.
- 4 Johnson DE, Appelt G, Samuels ML, Luna M. Metastases from testicular carcinoma. Study of 78 autopsied cases. *Urology*. 1976;8(3):234-9.
- 5 Miller TT, Mendelson DS, Wu LT, Halton KP. Seminoma of the testis presenting as an ulcerating mass of the duodenum. *Clin Imaging*. 1992;16:201-3.
- 6 Thompson JL, Blute ML. Coffee ground emesis: rare presentation of testicular cancer treated with neoadjuvant chemotherapy. *Urology* 2004, 64(2):376-377.