

## Skin disease linked to gadolinium prompts warning

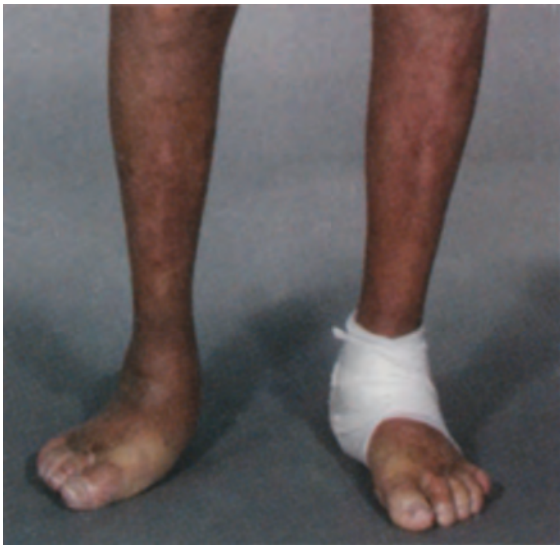The risk that some patients have for developing a debilitating, life-threatening skin disease linked to the administration of gadolinium calls for close scrutiny of kidney function or even a higher threshold of glomerular filtration rate.

Around 400 cases of nephrogenic systemic fibrosis (NSF) have been identified worldwide, and most are related to the administration of gadodiamide (Omniscan, GE Healthcare) in patients with moderate to end-stage kidney disease, according to Prof. Henrik Thomsen, a radiologist at Copenhagen University Hospital in Denmark.

Patients with a GFR of <30 mL/min and those on dialysis are at risk, Thomsen said. There also have been reports of patients with a serum creatinine below 2 mg/dL after gadodiamide administration, suggesting that the threshold could be set higher at <60 mL/min.

GE Healthcare has posted warnings about gadodiamide in its website.

*Emily Hayes*



52-year-old man with diabetes was exposed to 0.18 mmol/kg gadodiamide, while depending on hemodialysis. He developed severe nephrogenic systemic fibrosis, affecting his walking and most functional abilities of the upper extremities, including all finger movements. (Image courtesy of Dr. Peter Marckmann, department of nephrology at Copenhagen University Hospital in Herlev, Denmark).

*Taken from: Diagnostic Imaging Europe, April 2007, p. 9.*

## AUA new prostate-cancer treatment guidelines

ANAHEIM, CA, May 24, 2007. New guidelines for the treatment of prostate cancer were released on May 21<sup>st</sup> here at the American Urological Association (AUA) annual meeting. Additional treatment guidelines have been recommended based on consensus of the Prostate Cancer Clinical Guideline Update Panel. Men have a lifetime risk of 3% of dying from prostate cancer, while they have a 17% risk of getting prostate cancer. The previous guidelines have been in effect since 1995. Since then, 2.6 million men have been diagnosed with prostate cancer, and approximately 375,000 men have lost their lives to this disease. One new recommendation is that first-line hormone therapy is seldom indicated in patients with localised prostate cancer. An exception may be for the palliation

of symptomatic patients with more extensive or poorly differentiated tumours whose life expectancy is too short to benefit from treatment with curative intent. Another new recommendation is that the morbidities of androgen deprivation therapy (ADT) should be considered in the context of the existing comorbidities of the patient when choosing palliative ADT. Treatment complications are summarised and analysed in the new guideline, and quality-of-life and treatment decisions are discussed. The role of combined therapy is cited, and future research needs are listed. Randomised, controlled trial results are listed by author and summarised. The 2007 Update of the Guideline for the Management of Clinically Localised Prostate Cancer should be a very helpful tool for physicians in this new era of prostate-cancer treatment.

Please visit the link to the 2007 Guidelines at <http://www.auanet.org/guidelines>

*Laura Gater*

*Source: <http://www.docguide.com/news/content.nsf>*

## Sonoelastography makes headway in prostate cancer assessment

Sonoelastography shows strong performance in prostate cancer detection, but room for improvement remains when it comes to specificity, according to research from the Medical University Innsbruck in Austria, a leading center in prostate imaging research.

Sonoelastography has been in research stages for many years but has only recently approached the verge of entering clinical practice. The technique uses ultrasound to measure the elastic properties of tissues, based on the well-established principle that malignant tissue is harder than benign tissue. A color classification system registers tissue as benign (green) or malignant (blue). Prostate cancer is one of the most common cancers in men. As diagnostic testing with the prostate-specific antigen blood test has increased, so have the number of biopsies, with a high rate of negative results. Typically, biopsies are performed by urologists guided by gray-scale ultrasound, which suffers from low sensitivity.

The release of two new software upgrades in the last year and the availability of more effective probes have enhanced sonoelastography's performance in prostate imaging, according to Dr. Ferdinand Frauscher, director of urology at Medical University Innsbruck.

„We now have tools that provide better imaging information about tissue elasticity and enable better detection of suspicious lesions,” he said.

At ECR '07, the Innsbruck researchers presented two new papers about the technique's role in prostate imaging, based on results with a Hitachi ultrasound system. In the first study, of almost 500 patients, they found a very high correlation between sonoelastography and systematic biopsy results. Patients involved in the study had a PSA level over 1.5 ng/mL and underwent 10-core systematic biopsy. To overcome the challenge of getting adequate compression of the entire gland, the researchers used a narrower region of interest, examining the prostate in three sections: base, midgland, and apex.

According to systematic biopsy results, 125 patients had cancer. There were 321 cancerous areas, with Gleason scores ranging from 3 to 10. Confirmed results on biopsy showed that sonoelastography had very good sensitivity of 86% for the entire prostate organ but lower specificity of 72%. Of 533 findings,

the technique identified 275 false positives, due to mistaken assessments of areas with inflammation and atrophy. Sonoelastography performed best in cancers of the apex, with sensitivity of 79% and specificity of 85% to 93%. Performance of the organ.

„The results are promising, especially in atypical areas,” said Dr. Leo Pallwein, who presented results.

Another study from the same institution suggests sonoelastography can help determine whether cancer has spread beyond the capsule of the prostate gland (extracapsular extension). Making such a determination is crucial for selecting the most appropriate treatment.

Researchers performed sonoelastography and obtained contrast-enhanced T1- and T2-weighted MR images in 15 patients with elevated PSA levels prior to radical prostatectomy. Spectroscopy and image fusion were not performed with MR. Based on the histopathologic results, all cancers were well visualized with both sonoelastography and MRI. Surgery results indicated extracapsular extension in 11 of 15 cases. Sonoelastography showed infiltration of the capsule in eight patients and stiffness in seminal vesicles in four cases. MRI showed infiltration in the perioprostatic fat tissue in seven cases and infiltration of the seminal vesicles in five cases.

„Sonoelastography correlated well with MRI and histologic findings. It showed remarkable strength for prediction of extracapsular extension,” said Dr. Friedrich Aigner, the radiologist who presented the study results.

Emily Hayes

Taken from: *Diagnostic Imaging Europe*, June-July 2007, p. 6-8.

### Stromal invasion as prognosis factors in pT1 micropapillary pattern adenocarcinoma of the lung

Lung cancer is a leading cause of cancer-related deaths in highly industrialized countries of the West. Incidence of adenocarcinoma has permanently been increasing (1). Patients with small adenocarcinomas (<2.0 cm) have good prognosis if there are no distant metastases (2). Such clinical behavior suggests that lung adenocarcinoma is a heterogeneous disease, which has been confirmed by genomic researches. Apart from standard prognostic markers (TNM, pTNM assessment), Kawakami et al. recommend histological evaluation of tumor fibrosis and its invasion into the center of a fibrotic focus (3). Additionally, some authors report that the size of central fibrosis (4), presence of fibroelastic or elastic tissue (5), and desmoplasia proliferation might be reliable prognostic parameters. Stromal invasion grading system has been studied in papillary and micropapillary pattern adenocarcinomas (3). Table 1

Table 1. Relationship between grade of stromal invasion and micropapillary pattern

Stromal invasion grade	No. of cases	Micropapillary pattern-negative group (%)		Micropapillary pattern-positive group (%)	
		0	1+	2+	3+
Total	120	21 (18)	19 (16)	54 (45)	26 (22)
Grade 0	8	8 (100)	0 (0)	0 (0)	0 (0)
Grade 1	21	7 (33)	6 (29)	7 (33)	1 (5)
Grade 2	10	1 (10)	2 (20)	4 (40)	3 (30)
Grade 3	81	5 (6)	11 (14)	43 (53)	22 (27)

shows the relationship between stromal invasion grade and micropapillary pattern. In most cases (68%), invasion grade 3 has been identified and low positivity in other cases. Five-year survival rate for these patients was 63% (Figure 1), which means that patients with micropapillary pattern have poor prognosis. This histological pattern also gives poor prognosis in patients with carcinoma of the breast, bladder, ureter, and parotid gland (6,7). Initial molecular investigations only partially explain the phenomenon of heterogeneity. Genomic investigations of micropapillary pattern-positive cases confirm the loss of the short arm of chromosome 8(8p) (8). Genes EGR3, TRAIL receptors, DR4, DR5, SCAM1, and prostate specific homeobox gene NKX3A have been mapped in this region. MUC1 expression is also predominantly demonstrated in micropapillary pattern-positive carcinomas of the breast and colon. The expression of this membrane glycoprotein has been correlated to interaction of the cells and stroma or to the metastatization (3,9).

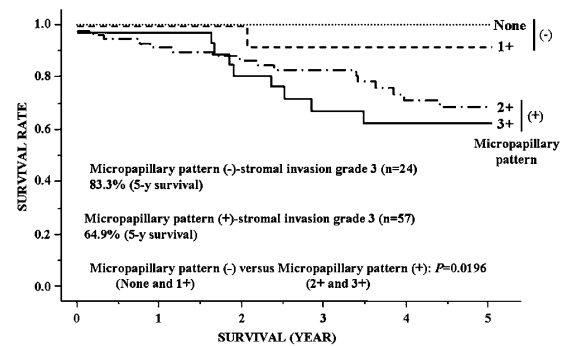


Figure 1. Survival rates of patients with stromal invasion grade 3 carcinomas according to presence or absence of a micropapillary pattern. The prognosis of patients with micropapillary pattern-negative (None and 1+) stromal invasion grade 3 adenocarcinoma was significantly better than those with micropapillary pattern-positive (2+ and 3+) tumors (log rank test, P = 0.0196) (ref. 3)

#### REFERENCE

- 1 Kuroishi T, Nishikawa Y, Tominaga S, et al. Cancer mortality statistics in 33 countries (1954–1992). In: Tominaga S, Oshima A, eds. *Gann Monograph on Cancer Res No. 47: Cancer Mortality and Morbidity Statistics*. Tokyo: Japan Scientific Societies Press; 1999. p. 153–217.
- 2 Kurokawa T, Matsuno Y, Noguchi M, et al. Surgically curable ‘early’ adenocarcinoma in the periphery of the lung. *Am J Surg Pathol* 1994;18:431-8.
- 3 Kawakami T, Nabeshima K, Makimoto Y, et al. Micropapillary pattern and grade of stromal invasion in pT1 adenocarcinoma of the lung: usefulness as prognostic factors. *Modern Pathol* 2007;20:514-21.
- 4 Suzuki K, Yokose T, Yoshida J, et al. Prognostic significance of the size of central fibrosis in peripheral adenocarcinoma of the lung. *Ann Thorac Surg* 2000;69:893-7.
- 5 Eto T, Suzuki H, Honda A, et al. The changes of the stromal elastotic framework in the growth of peripheral lung adenocarcinomas. *Cancer* 1996;77:646-56.
- 6 Michal M, Skalova A, Mukensnabl P. Micropapillary carcinoma of the parotid gland arising in mucinous cystadenoma. *Virchows Arch* 2000;437:465-8.
- 7 Nagao T, Gaffey TA, Visscher DW, et al. Invasive micropapillary salivary duct carcinoma: a distinct histologic variant with biologic significance. *Am J Surg Pathol* 2004;28:319-26.
- 8 Thor AD, Eng C, Devries S, et al. Invasive micropapillary carcinoma of the breast is associated with chromosome 8 abnormalities detected by comparative genomic hybridization. *Hum Pathol* 2002;33:628-31.
- 9 Pettinato G, Manivel CJ, Panico L, et al. Invasive micropapillary carcinoma of the breast: clinicopathologic study of 62 cases of a poorly recognized variant with highly aggressive behavior. *Am J Clin Pathol* 2004;121:857-66.

Vladimir Baltić

## Prognostic value of p53 expression in ovarian cancer

Ovarian cancer is the leading cause of death among patients with gynecological cancers. There is no proven method in prevention and often the disease is diagnosed in advanced stage.

After surgery, standard treatment modality of ovarian cancer is chemotherapy with taxanes and platinum-based regimens. The only validated marker for ovarian cancer is CA 125, which is detectable in the serum of >80% of women with ovarian carcinomas. CA 125 is, however, reliable only in monitoring response to treatment or disease recurrence and not as a diagnostic or prognostic marker. Therefore, considerable interest lies in identifying molecular prognostic indicators to guide treatment decisions.

A. Psyrri, from Yale Cancer Center in New Haven, Connecticut, and co-workers investigated the prognostic potential of p53 protein expression in 141 patients with ovarian cancer. They measured p53 protein expression using an immunofluorescence-based method of automated *in situ* quantitative measurement of protein analysis (AQUA).

Protein p53 is regarded as a valuable prognostic marker in cancer with a potential use as a molecular target. A tissue array that composed of 141 advanced stage ovarian cancers uniformly treated was constructed. For evaluation of p53 protein expression, they used immunofluorescence-based method of automated *in situ* quantitative measurement of protein analysis (AQUA).

They showed as a result that high nuclear p53 expression levels were associated with better outcome for overall survival (OS) ( $P = 0.0023$ ) and disease-free survival ( $P = 0.0338$ ) at 5-years. High cytoplasmic p53 expression levels were associated with better outcome for OS ( $P = 0.0002$ ). In multivariable analysis, high nuclear and high cytoplasmic p53 level with International Federation of Gynecology and Obstetrics (FIGO) stage were the most significant predictor variables for OS and high nuclear p53 level with FIGO stage were the significant predictor variables for disease-free survival.

In conclusion, they point that assessment of the prognostic value of p53 protein levels using conventional immunohistochemistry is limited by the nonquantitative nature of the method. AQUA provides precise estimation of p53 protein levels and is able to elucidate the association of p53 protein levels and ovarian cancer prognosis.

### REFERENCE

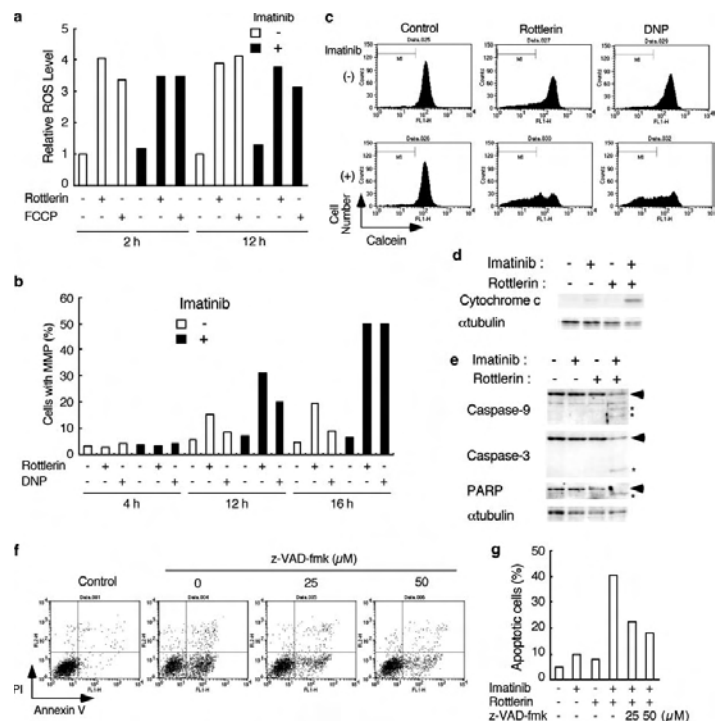
- 1 Psyrri A, Kountourakis P, Yu Z, Papadimitriou C, Markakis S, Camp RL, et al. Analysis of p53 protein expression levels on ovarian cancer tissue microarray using automated quantitative analysis elucidates prognostic patient subsets. *Ann Oncol* 2007;18(4):709-15.

Aljoša Mandić

## Rottlerin enhances imatinib-induced apoptosis

Chronic myeloid leukemia (CML) and about 30% to 40% of acute lymphoblastic leukemia are characterized by reciprocal chromosomal translocation t(9;22), which generates the BCR/ABL fusion gene. The product of this gene is a tyrosine kinase that is constitutively activated and contributes to the proliferation of hematopoietic BCR/ABL+ cells by the activation of various intracellular signaling pathways: Ras, Rap 1, B/Raf, Raf-1, ERK, P13K, STAT 5, and NFkB (1). Imatinib (STI-571) inhibits the activity of BCR/ABL and thus hinders the proliferation and induces apoptosis of BCR/ABL-expressing leukemic cells *in vitro*. Imatinib is highly effective in the treatment of CML or Ph chromosome-

positive ALL. However, treatment (lasting several months) of the patients with CML or ALL in advanced stages of disease may develop resistance to imatinib due to the appearance of mutations in the BCR/ABL kinase domain. The most frequent mutations are E255K and T3151 (2). The existing resistance creates the development of new leukemic clones. To overcome the imatinib resistance new drugs and new treatment strategies are being investigated. ABL inhibitors dasatinib and AMN107 are effective in the treatment of some types of CML but not those that lack T3151 mutations (3). Kurosou et al (2007) show that rottlerin synergistically with imatinib induces apoptosis of BCR/ABL leukemia resistant cells. Mechanism of apoptosis is activated through the decline of  $\Delta\psi_m$  mitochondrial membranes; they become less resistant to cytochrome c, which activates caspase-3 and caspase-9 in cytosol and induces apoptotic processes. Pan-caspase inhibitor z-VAD-fmk can only partly inhibit synergistic induction of apoptosis by imatinib and rottlerin (Figure 1) (4,5).



**Figure 1.** Synergistic induction of apoptosis in K562 cells by imatinib and rottlerin is induced through MMP leading to the cytochrome c release and activation of caspases-3 and -9. (a) K562 cells were treated for indicated times with 1  $\mu\text{M}$  imatinib, 2  $\mu\text{M}$  rottlerin, or 10  $\mu\text{M}$  FCCP, as indicated. Cells were subjected to the flow cytometric analysis for ROS by using the fluorescent probe HE. The mean fluorescent intensity, normalized by that of cells treated without any reagent for 2 h, is plotted. (b, c) K562 cells were preincubated with calcein-AM and CoCl<sub>2</sub> for 15 min and subsequently cultured for indicated times (b) or for 16 h (c) with 2  $\mu\text{M}$  rottlerin, 0.5  $\mu\text{M}$  DNP, or 1  $\mu\text{M}$  imatinib, as indicated. Cells were then subjected to the flow cytometric analysis for calcein fluorescence in mitochondria, and percentages of cells undergoing MMP and exhibiting the decreased fluorescence are plotted in b. (d, e) K562 cells were treated with 1  $\mu\text{M}$  imatinib or 2  $\mu\text{M}$  rottlerin, as indicated, for 24 cells. Cytoplasmic extracts (d) or total cell lysates (e) were harvested and subjected to Western blot analysis with antibodies against indicated proteins. Positions of full-length or cleaved proteins are indicated with arrows or asterisks, respectively. (f) K562 cells were left untreated for control or treated with 1  $\mu\text{M}$  imatinib and 2  $\mu\text{M}$  rottlerin in the presence of indicated concentrations of z-VAD-fmk for 24 h. Cells were then stained with Annexin V-FITC as well as PI and analysed by flow cytometry. (g) K562 cells were treated with 1  $\mu\text{M}$  imatinib, 2  $\mu\text{M}$  rottlerin, and 25 or 50  $\mu\text{M}$  z-VAD-fmk, as indicated, for 24 h, and percentages of cells staining positive for Annexin V are plotted (ref. 5)

Harper JA (2001) suggested a new approach to a safety treatment of CML with mitochondrial uncoupler DNP which FDA prohibited DNP in 1938 because of its side effects (cataract and unexpected deaths). However, investigations of other uncouplers, including UCP-1, UCP-2, and UCP-3 have been initiated with the aim to evaluate their therapeutic potential (5).

REFERENCE

- 1 Goldman JM, Melo JV. Chronic myeloid leukemia – advances in biology and new approaches to treatment. *N Engl J Med* 2003;349:1451-64.
- 2 O'Hare T, Corbin AS, Druker BJ. Targeted CML therapy: controlling drug resistance, seeking cure. *Curr Opin Genet Dev* 2006;16:92-9.
- 3 Weisberg E, Manley PW, Breitenstein W, et al. Characterization of AMN107, a selective inhibitor of native and mutant Bcr-Abl. *Cancer Cell* 2005;7:129-41.
- 4 Harper JA, Dickinson K, Brand MD. Mitochondrial uncoupling as a target for drug development for the treatment of obesity. *Obes Rev* 2001;2:255-65.
- 5 Kurosu T, Tsuji K, Kida A, et al. Rottlerin synergistically enhances imatinib-induced apoptosis of BCR/ABL-expressing cells through its mitochondrial uncoupling effect independent of protein kinase C-d. *Oncogene* 2007;26:2975-87.

Vladimir Baltić