



Ki-67 expression in squamous intraepithelial lesions of the uterine cervix

Milana Panjković¹, Tatjana Ivković-Kapic²

ABSTRACT

BACKGROUND: Uncontrolled cell proliferation and malignant transformation are the basic elements in the development of malignant disease including cervical cancer and its precursors. The aim of this study was to investigate the proliferative activity by using Ki-67 proliferative marker according to CIN grade.

METHODS: We used immunohistochemical methods to study the expression of the proliferative marker Ki-67 in the specimens of 5 patients with normal cervical epithelium, 7 with CIN1, 13 with CIN2, and 25 patients with CIN3 grade of the cervical intraepithelial lesions.

RESULTS: All cases with normal cervical epithelium and all those with CIN1 changes had negative proliferative Ki-67 index. Ki-67 positive proliferative index was found in 5 (38.46%) and 17 (68%) of patients with CIN2 and CIN3 changes respectively. There was a clear trend for increasing number of cases with positive Ki-67 index with increasing CIN grade. High significant difference of Ki-67 expression was found between patients with CIN1 and CIN2 lesions ($t=2.9$; $p<0.01$). Ki-67 positive cells were distributed only in the lower third of the epithelial layer in CIN1 cases. Seven (53.8%) and 13 (52%) of patients with CIN2 and CIN3 changes respectively, had Ki-67 positive cells in the lower and middle third of the epithelial layer, while 3 (23.1%) and 10 (40%) of cases with the same dysplastic changes had Ki-67 positive cells distributed in lower, middle and upper third of the epithelium. Difference of the Ki-67 positive cells distribution was highly significant between patient with CIN1 and CIN2 epithelial changes.

CONCLUSION: The present study shows that there is statistically significant relation between proliferative activity, distribution of Ki-67 positive cells, and CIN grade. Ki-67 antigen could be a tool to identify women who are at higher risk for progression and/or recurrence of cervical squamous precancerous lesions.

KEY WORDS: Cervix Neoplasms; Ki-67 Antigen; Cervical Intraepithelial Neoplasia; Tumor Markers, Biological; Immunohistochemistry

¹Institute of Pulmonary Diseases, Sremska Kamenica, ²Institute of Oncology Sremska Kamenica, Sremska Kamenica, Serbia; Address correspondence to: Dr. Milana Panjković, Institut of Pulmonary Diseases, 21204 Sremska Kamenica, Institutski put 4, Serbia; The manuscript was received: 23.02.2006, Provisionally accepted: 16.03.2006, Accepted for publication: 08.05.2006

©2006, Institute of Oncology Sremska Kamenica, Serbia

INTRODUCTION

Uncontrolled cell proliferation and malignant transformation are the basic elements in the development of cancer including cervical cancer and its precursors. Better understanding of cell proliferation activity allows a more rational therapeutic approach (1). Loss of genomic integrity is a defining feature of many human malignancies, including human papilloma virus associated preinvasive cervical intraepithelial neoplasms (CIN) and invasive cervical squamous lesions (2,3). The centrosome is a cytoplasmic organelle consisting of a pair of centrioles surrounded by a pericentriolar matrix. Each cell contains one or, before a cell division, two centrosomes. During mitosis, the two centrosomes form the poles of a bipolar mitotic spindle, a function that is essential for accurate chromosome segregation. HPV E6 and E7 oncoproteins play distinct roles in this process by targeting different pathways. Whereas E6 may promote genetic instability by inactivating the tumor suppressor protein p53, E7 subverts the integrity of the host cell genome by disregulation of Rb-E2F complex and activation G1 to S-phase of cell cycle. E7 oncoprotein rapidly induces abnor-

mal centrosome duplication, whereas acute expression of HPV 16 E6 does not affect centrosome number. Cells expressing both oncoproteins showed most pronounced alterations of centrosome numbers, mitotic spindle poles and genomic integrity. High risk HPV E6 and E7 oncoproteins cooperate to induce centrosome-related mitotic aberrations resulting aneuploidy. In contrast, cells expressing low-risk HPV6 E6 and E7 proteins showed no such abnormalities. Most cells with abnormal centrosomes are unable to complete mitosis. Small number of cells progress through mitosis. Daughter cells derived abnormal mitoses are likely to have acquired genomic changes (2-6).

The presence of abnormal mitotic figures (AMF), as well as polarity loss and cellular atypia are morphological signs of cervical intraepithelial neoplasia. Different types of AMF have been found in those lesions including lag type mitoses, and their variants, multipolar mitoses and the others. Strong association between the occurrence of lag type mitoses and CIN grade was found (7).

The aim of this study was to investigate the proliferative activity by using Ki-67 proliferative

marker, as well as distribution of Ki-67 positive cells through the epithelial layer according to the CIN grade.

MATERIAL AND METHODS

Specimen of 45 cone biopsy were selected from the archives of the Department of Pathology, Institute of Oncology, Sremska Kamenica. Those cases were classified as CIN1 (n=7), CIN2 (n=13), CIN3 (n=25).

The tissue had been fixed in buffered 4% formaldehyde, embedded in paraffin, cut at 4 μ, and stained with hematoxylin and eosin (HE). Paraffin sections of 4 μ thickness adjacent to the HE sections used for CIN grade assessment, were mounted onto Super Frost Plus Slides and dried overnight at 37°C. The streptavidin-biotin peroxidase complex method was used for immunohistochemistry. Briefly, sections were dewaxed, and hydrated through graded alcohols to water.

Immunostaining for Ki-67 (DAKO Glostrup, Denmark) was carried out. Following endogenous peroxidase and protein blocking step, the slides were incubated with primary antibodies. After brief washes, incubation in a cocktail of biotinylated rabbit anti-mouse IgG/IgM for 30 min was performed.

The sections were then washed and incubated with streptavidin-biotinylated horseradish peroxidase complex for 30 min, reacted with 3-amino-9-ethylcabazole (AEC, DAKO) and hydrogen peroxide. To visualize the end product hematoxylin was used as counter stain. Sections stained for Ki-67 were assigned scores of 0-3, with 0 meaning no staining; 1, weak positive, the mounts of positive cells are less than 10%; 2, positive, the mounts of positive cells are more than 10% but less than 50%; and 3, strong positive, the mounts of positive cells are more than 50%. Scores 0 and 1 were counted as negative and scores 2 and 3 as positive cases (8). Nuclear staining was evaluated.

To investigate significant differences between the three CIN grades, Student test was performed.

χ² test was used to calculate the topography differences of Ki-67 expression between CIN grades. The level of significance was set to p<0.05.

RESULTS

The mean age of all patients was 36.4±5.53 years. The mean age of patients with dysplastic epithelial changes grade CIN1, CIN2 and CIN3 were 36.7±7, 36.8±7 and 36.2±5 years respectively. There was no statistical significance between grade of CIN changes and patient age. Immunoreactive Ki-67 positive cells showed dark brown, homogenous or punctate staining, limited exclusively to the nucleus (Figure 1).

All cases with CIN1 changes had negative proliferative Ki-67 index. Ki-67 positive proliferative index was found in 5 (38.46%) and 17 (68%) of patients with CIN2 and CIN3 changes respectively (Figure 2). There was a clear trend for increasing number of cases with positive Ki-67 index with increasing CIN grade, although no significant difference was found between cases with CIN2 and CIN3 changes (t=1.9; p>0.05). High significant difference was found between patients with CIN1 and CIN2 lesions (t=2.9; p<0.01).

We also investigate distribution of Ki-67 positive nuclei through the cervical epithelial layer (Figure 3). Ki-67 positive cells were distributed only in the lower third of the epithelial layer in CIN1 cases. 7 (53.8%) and 13 (52%) of patients with CIN2 and CIN3 changes respectively, had Ki-67 positive cells in the lower and middle third of the epithelial layer, while 3 (23.1%) and 10 (40%) of cases with the same dysplastic changes had Ki-67 positive cells distributed in lower, middle and upper third of the epithelium. No significant difference was found in the distribution of Ki-67 positive cells between CIN2 and CIN3 cases (χ²=2.91), while that difference was highly significant between patient with CIN1 and CIN2 epithelial changes (χ²=9.04, p<0.005).

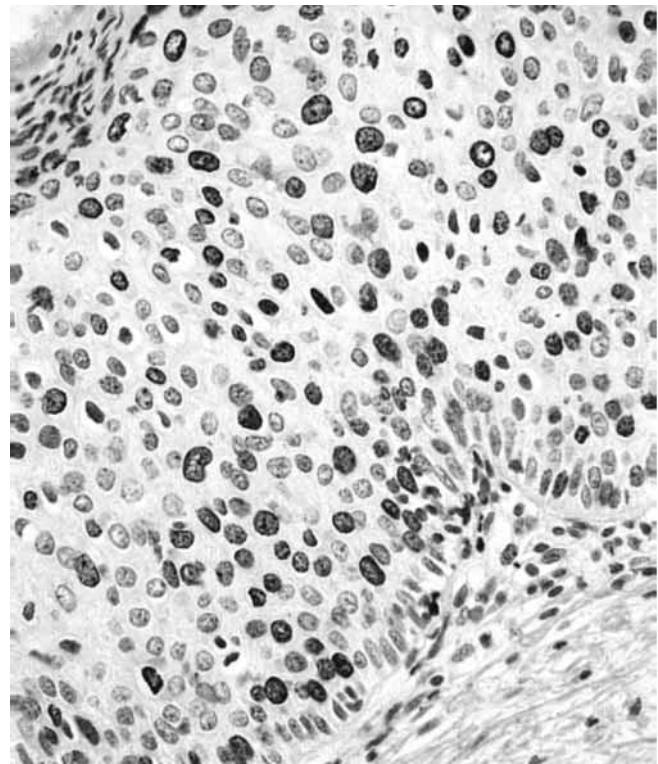


Figure 1. Expression of the Ki-67 antigen in the dysplastic cervical epithelium, x200

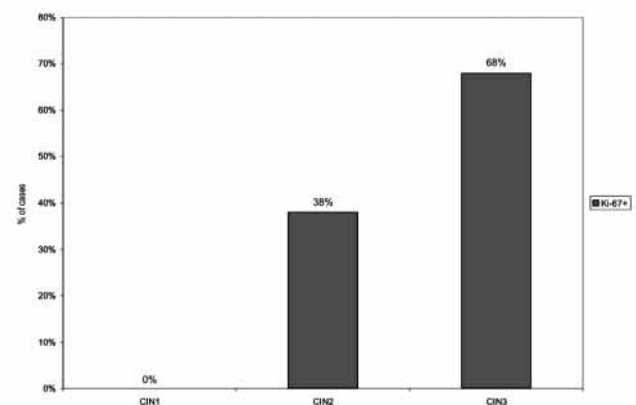


Figure 2. Ki-67 expression according to the CIN grade

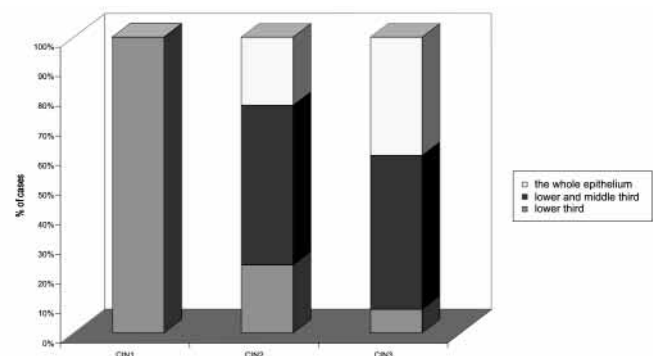


Figure 3. Distribution of the Ki-67 positive cells through dysplastic cervical epithelium

DISCUSSION

Cell proliferation can be followed up by the expression of some cell proteins such as PCNA and Ki-67 antigen. Ki-67 is a nuclear antigen expressed during G1, S, M and G2 periods of cell cycle. The expression level of Ki-67 indicated the status of cell proliferation. Some stud-

ies have showed that Ki-67 protein could be a biomarker in the evaluation of the proliferative activity and progressive potential of normal, dysplastic and neoplastic changes (9,10). Our results showed that there was significant relation between the proliferative Ki-67 activity and CIN grade. Statistical difference between CIN1 and CIN2 group was significant, while no significant difference between CIN2 and CIN3 group of cases was found. We have also found differences of the Ki-67 positive cell distribution according to the CIN grade. There was a clear trend for increasing number of cases with Ki-67 positive cells in the middle and upper third of the epithelial layer with increasing CIN grade, although there was statistically significant difference only between CIN1 and CIN2 grade. Cases with CIN2 and CIN3 lesions showed considerable overlap.

Kruse et al. (10) have found that there was a significant relation between CIN grade and number of Ki-67 positive cells by using QPRODIG image analyzing system. The distribution of Ki-67 positive cells was related with CIN grade but there was overlap between CIN2 and CIN3 lesions like in our study.

The therapeutic significance of the distinction between CIN2 and CIN3 varies in different centers and can be important. It may thus be that CIN2 cases consist of two biologically different subgroups, which makes it tempting to speculate that this difference is due to the absence or presence of oncogenic human papilloma virus (10).

Tjalma's et al. (1) results have shown the presence of link between the increase in proliferative activity in CIN3 lesions, expressed as PCNA immunoreactivity and a risk of recurrence, and the great heterogeneity of PCNA expression in CIN3 lesions. CIN3 lesions with high proliferative activity are probably at higher risk to undergo genetic changes that may lead to recurrent CIN or invasive disease.

The results of al-Saleh's (11) study were similar. They also have found that HPV 16/18 cervical epithelial changes were significantly associated with higher densities of Ki-67 positive cells than HPV 6/11 positive type of cervical lesions. Similar changes were found in pre-cancerous esophageal lesions (8).

Sahebali et al. (12) performed Ki-67 immunostaining in cervical cytology samples. There were a significantly higher number of immunopositive cells in high-grade squamous intraepithelial lesions as well as in HPV16 positive samples. The infection of cervical cells by HPV manifests itself by changes in the function or expression of the host genes, and the detection of these alterations can play a role in diagnosis. These changes cause dysregulation of the cell cycle, manifested by abnormal proteins such as Ki-67. The detection of abnormal expression can identify clinical important cases of HPV infection with risk of progression towards dysplasia and carcinoma (12).

Ki-67 proliferative marker is very important for predict the value for progression of CIN1 and CIN2 lesions but according to recent studies it is not enough. Kruse et al. showed that other markers are also important such as Rb-positive nuclei in the deeper half of the epithelium and the proportions of CK13 and CK14-positive cells (4). Expression of p16 is also an important prognostic factor, which is connected with the expression of Rb-E2F complex and influence of E7 oncoprotein on it (4-6).

CONCLUSION

Although the present study shows that there is statistically significant positive relation between proliferative activity, distribution of Ki-67 positive cells and increasing CIN grade, it is based on statistics of a small number of cases so further investigations are needed.

REFERENCES

1. Tjalma W, Weyler J, Pollefiet C, Bogers J, Marck VE, Dam P, et al. The evaluation of proliferative activity in CIN III and microinvasive cervical cancer and its role of recurrence. *Eur J Obstet Gynecol Reproduct Biol* 2001;94(2):270-5.
2. Duensing S, Lee LY, Duensing A. The human papilloma virus type 16 E6 i E7 oncoproteins cooperate to induce mitotic defect and genomic instability by uncoupling centrosome duplication from the cell division cycle. *Proc Natl Acad Sci* 2000;97(18):10002-7.
3. Duensing S, Munger K. Centrosomes, genomic instability, and cervical carcinogenesis. *Crit Rev Eukaryot Gene Expr* 2003;13(1):9-23.
4. Kruse AJ, Skaland I, Janssen EA, Buhr-Wildhagen S, Klos J, Arends MJ, et al. Quantitative molecular parameters to identify low-risk and high-risk early lesions; role of markers of proliferative activity and differentiation and Rb availability. *Int J Gynecol Pathol* 2004;23(2):95-6.
5. Klaes R, Friedrich T, Spitkosky D, Ridder R, Rudy W, Petry U, et al. Overexpression of p16 (INK4A) as a specific marker for dysplastic and neoplastic epithelial cells of the cervix uteri. *Int J Cancer* 2001;92(2):276-84.
6. Sano T, Oyama T, Kashiwabara K, Fukuda T, Nakajima T. Expression status of p16 protein is associated with human papillomavirus oncogenic potential in cervical and genital lesions. *Am J Pathol* 1998;153(6):1741-8.
7. Leeuwen AM, Pieters WJ, Hollema H, Burger MPM. Atypical mitotic figures and the mitotic index in cervical intraepithelial neoplasia. *Virchows Arch* 1995;427:139-44.
8. Xu M, Jin YL, Fu J, Huang H, Chen SZ, Ping Q, et al. The abnormal expression of retinoic acid receptor, p53 and Ki-67 protein in normal, premalignant and malignant esophageal tissues. *World J Gastroenterol* 2002;8(2):200-2.
9. Calore EE, Manzione CR, Nadal SR, Cavalieri MJ, Calore NMP, Santos RPI. Ki-67 expression in anal intraepithelial neoplasia in AIDS. *Sao Paulo Med J* 2001;119 (3):201-6.
10. Kruse AJ, Baak JPA, Bruin PC, Jiwa M, Sniijders W, Boedt GF, et al. Ki-67 immunohistochemistry in cervical intraepithelial neoplasia (CIN): a sensitive marker for grading. *J Pathol* 2001;193:48-54.
11. al-Saleh W, Delvenne P, Greimers R, Fridman V, Doyen J, Boniver J. Assessment of Ki-67 antigen immunostaining in squamous intraepithelial lesions of the uterine cervix. Correlation with the histologic grade and human papillomavirus type. *Am J Clin Pathol* 1995;104(2):154-60.
12. Sahebali S, Depuydt CE, Segers K, Vereecken AJ, Marck EV, Bogers JJI. Ki-67 immunocytochemistry in liquid based cervical cytology: useful as an adjunctive tool? *J Clin Pathol* 2003;56:681-6.