



Boban ĐORĐEVIĆ
Ljubomir PANAJOVIĆ
Miloš PAVLOVIĆ

MEDICAL ACADEMY BELGRADE, BELGRADE, SERBIA

The role of plastic surgery in treatment of primary skin melanoma

KEYWORDS: Surgery, Plastic; Skin Neoplasms; Melanoma

INTRODUCTION

Melanoma of the skin is the most important tumor of the melanocyte system and it is one of the most aggressive solid tumors. Skin melanoma is characterized by the high malignant potential and the disease is potentially fatal. The incidence is in constant rise, especially in white population under 40 years all around the world.

Etiology of melanoma is not clearly defined but the risk factors are well defined. The high risk factors include: genetic predisposition (structural changes on chromosomes), skin type (white population with light skin, red or blond hair and light eyes), presence of certain pigmented changes on the skin (freckles, dysplastic nevus), overexposure to UV lights, sun burns in early childhood and type of work (2).

Early diagnostics and surgical treatment are the key to the successful treatment of disease. Early detection of melanoma is possible in large number of cases based on the clinical characteristics of melanoma (seven point check list, ABCDEF criteria) and additional diagnostic tools (computerized dermatoscopy, epiluminescent microscopy, ultrasonography)(3). One of the superior diagnostic methods is excisional biopsy because diagnosis is set up based on histopathological exam.

Skin melanoma could rise from preexisting nevi but we should keep in mind the fact that in 70%-80% of cases melanoma is developed de novo, without preexisting skin change, and in large percentage melanoma has resemblance to benign skin lesion (4,5). That is the reason why we should perform biopsy of every suspicious skin lesion. The defect after biopsy is small and the wound could be closed by direct suture which makes this procedure easy to perform by all surgeons or dermatologist (dermato surgeons).

Nowadays, the treatment of melanoma still represents a problem. American Joint Committee on Cancer (AJCC) published in 2006. new TNM classification of melanoma and the new staging system for skin melanoma (6). The basic prognostic factors in treatment of melanoma are classification according to histopathological type, Breslow and Clark classification, mitotic index on

mm², presence or absence of ulceration of primary melanoma, number of metastatic lymph nodes and presence of satellite metastases. All prognostic factors are directly connected to the patient's immune status (6).

Surgical treatment is the ultimate modality of treatment of primary melanoma and has its place in all stages of disease (7,8). Today, instead of old Handley's rule of excision on 5 cm distance of the lesion, we use narrower excisions. The width of excision is determined by the histopathological type and thickness of primary melanoma. Below are the proposed excision margins (9,10):

- for superficial and early melanoma – 1cm,
- for melanoma of medium thickness (from 2 to 4 mm) – 2 cm and
- for advanced melanoma (>4mm) – 2 to 3 cm.

The fear of postoperative deformities due to the proposed excision margins should not limit the surgical treatment of melanoma. The excision should be performed by the experienced surgeon who well knows the anatomy of the region affected by melanoma, and who has mastered various reconstructive techniques from the basic ones (direct suture and skin transplant) to the most complex ones (local, regional and microvascular transplant) (11,12). The type of reconstruction performed depends upon localization of primary melanoma, radicality of excision, complexity of the defect after excision (simple defect – defect on skin only and complex defect – defect of the skin and underlying structures). The defects on the face, hands, feet, breasts and perineum have a special place in reconstruction due to its complex functional structures and important esthetic value (13).

We would like to point out the position of plastic surgery in the surgical treatment of primary skin melanoma and to by retrospective analysis show the basic types of reconstructive procedures performed after radical excision of primary skin melanoma

METHODS

In the period between January 2003 to December 2005 at the Clinic for Plastic Surgery and Burns of the Military Medical Academy in Belgrade we treated 107 patients with primary skin melanoma – 58 male and 49 female patients. The average age of our patients was 53. In all patients we performed in the same act radical excision with frozen section analysis and the primary reconstruction of the defect. We performed additional sonography and other radiological procedures postoperatively to detect the regional and distant metastatic spots. After obtaining definite histopathological analysis the team of doctors decides on further modalities of treatment. We analyzed and presented our results based on the localization of the lesion, invasion and thickness of tumor as well as the type of reconstruction of the postexcisional defect.

RESULTS

Primary skin melanoma was most commonly found on the back, arm and leg. In 9.3% of patients primary skin melanoma was localized on the head, in 2.8% on the hair bearing skin of the head and in 6.5% in other regions of the head. In 9 patients primary melanoma was found on the foot, 3 patients had melanoma on the toe skin and one patient had it subungual (Table 1).

Based on the histopathological type we can see that nodular type of melanoma is dominant while lentigo melanoma is rare (Figure 1).

Analysis of microscopic classification on melanoma according to Breslow and Clark showed that majority of our patients has advanced melanoma which determined the radicality of excision and the type of reconstructive procedure (Figures 2, 3).

Respecting the current recommendations about width of excision around primary melanoma most of the wounds on the body could be closed up with direct sutures or autotransplants. Postexcisional defects on the head, face, foot and hand could be reconstructed using local skin flaps. Skin flaps we also used in other regions when needed (Figures 4,5).

Address correspondences to:

Boban Đorđević, Clinic for Plastic Surgery and Burns, Military Medical Academy, Crnotravska 17, 11002 Belgrade, Serbia

The manuscript was received: 15.09.2006

Accepted for publication: 25.09.2006

Table 1. The most common localizations of primary skin melanoma (period 2003-2005)

Localisation of primary melanoma	2003	2004	2005	Total number of melanoma	%
head and neck	2	3	5	10	9.34
shoulder	2	1	1	4	3.74
upper arm	4	6	4	14	13.08
fore arm	2	0	3	5	4.67
hand	0	1	1	2	1.87
chest	1	4	2	7	6.54
back	8	12	9	29	27.10
abdomen	2	0	2	4	3.74
upper arm	2	4	5	11	10.28
lower leg	3	4	5	12	11.21
foot	2	3	4	9	8.41
total	28	38	41	107	100.00

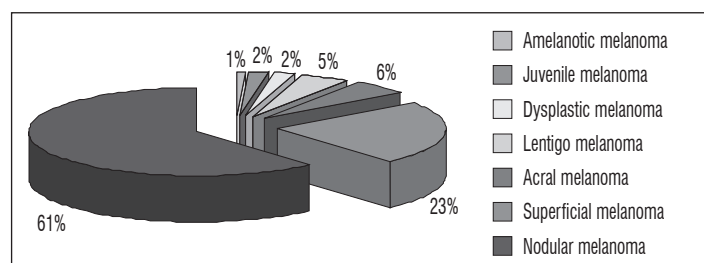


Figure 1. Histopathological types of melanoma

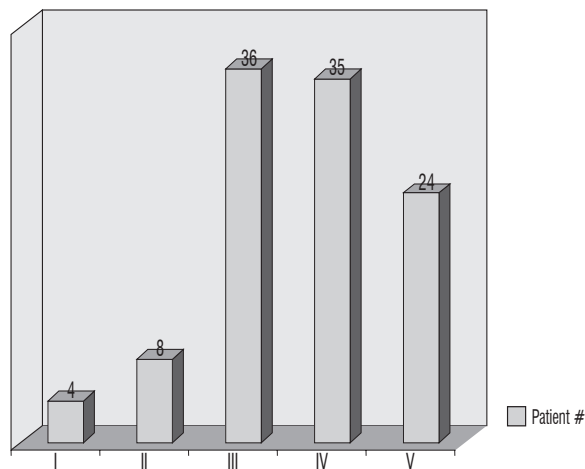


Figure 2. Melanoma stages according to Clark's classification

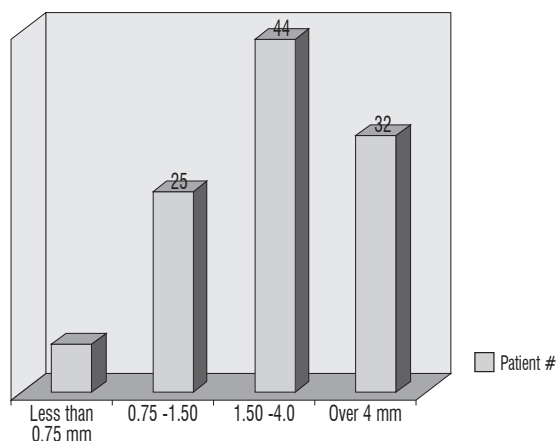


Figure 3. Thickness of melanoma according to Breslow

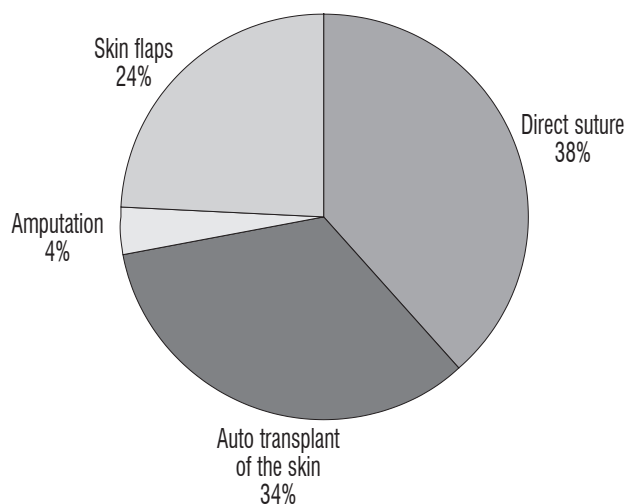


Figure 4. Distribution of surgical interventions

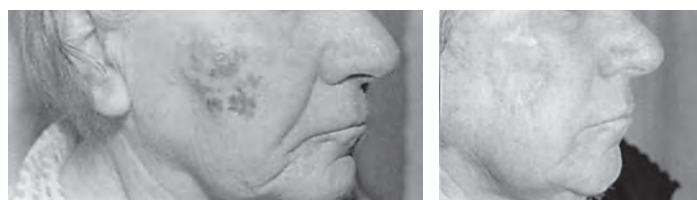

Figure 5. Melanoma on the face – preoperative and postoperative view

DISCUSSION

Surgical treatment of skin melanoma is performed in all stages of the disease. It includes excision of primary melanoma, regional lymph node dissection and treatment of intransit and distant metastases.

An adequate surgical treatment of primary melanoma and regional metastases is exclusive domain of plastic and reconstructive surgery and oncologic surgery (5,7,8).

Treatment of distant metastases is performed by the surgeons trained in the field of oncologic surgery.

Design of the excision is dictated by the nature of the skin lesion and by the rules of plastic surgery which provides optimal functional, esthetic, psychosocial and economic results in the initial stage of treatment. Knowing all capabilities of plastic and reconstructive surgery frees the surgeon to be as radical as necessary (14).

Contemporary trend in the surgical treatment of primary skin melanoma suggests that skin autotransplant should not be used because it prolongs recovery period without providing satisfactory functional and esthetic results. Keeping in mind that the type of reconstructive procedure does not affect metastatic potential of melanoma and survival of the patients (if the resection margins are tumor free), we suggest reconstruction by using skin flaps. Postexcisional defects on the abdomen, chest and back can be directly sutured or closed by perioperative adjacent skin expansion (15,16).

In the past skin autotransplant was always used in reconstruction of the defect. In our series we used it only in certain number of patients with defects on abdomen, chest and back, dorsal side of the foot, calf, hair bearing skin of the head and to cover up secondary defects created in reconstruction of large defects of the hair bearing skin of the head.

In the reconstruction of defects different types of local skin flaps could be used – transpositional, rotational and slide flaps, providing faster recovery (17). In certain cases microvascular flaps could be used (13).

In our series we used skin flaps in 24% of patients. The size and extensity of the defect on the hair bearing skin of the head forced us to use skin autotrans-

plant and in the cases when the bone was exposed we covered up the defect first by skip flap and then secondary defect by the skin autotransplant.

Postexcisional defects on the face, especially on the cheek, could be closed by direct suture. In the cases when that is not possible we tried to design a local skin flap which had similar color and texture. We used most commonly rotational, transpositional (Limberg flap) and sliding flap (18).

Postexcisional defect on the nose could be reconstructed by using skin autotransplant with its full thickness and if the cartilage is exposed we could use some of the regional skin flaps (bilobar Banner, nasolabial, Reinger, frontal, etc). In our series we used both types of reconstruction (19,20).

In the melanoma localized on the skin of the ear it is considered that ear cartilage represents a barrier and postexcisional defect can be reconstructed with skin autotransplant or the skin flap that is used when reconstructing partial defect of the ear lobe (21).

Narayan proposes that the safer method is the excision of the melanoma or partial amputation of the ear lobe with primary or secondary reconstruction (17). We agree with Narayan's proposal but we think that it is better to reconstruct the defects of the helix in the second act. We think that the indications for the amputation of the ear lobe are reserved only for extensive primary melanomas or large rest tumors.

Melanomas localized on the eye lids and periorbital region are very challenging for plastic surgeons due to its complex anatomy and difficult reconstruction (22).

Spinelli and associates divided periorbital region into five zones and suggested a reconstruction method for each region (23).

Postexcisional defect on the upper eye lid in one patient we reconstructed using transpositional flap and in second patient with defect in the region of medial cantus we reconstructed using globular flap.

Melanoma localized on the hand and foot could be reconstructed by using skin autotransplant or by skin flap, specially when the lesion is localized on the plantar side of the foot (24,25).

Subungual melanoma requires amputation of the distal phalange. In the cases when the melanoma is localized on the skin of phalange total amputation is indicated²⁶. In our series we used all of the reconstruction methods described and in four patients we performed amputation of the finger.

CONCLUSION

Postexcisional defect is determined by the histopathological type and the thickness of melanoma. The guidelines and recommendation on excision margins should be followed strictly.

Contemporary trends in the surgery of melanoma consider creating minimal postexcisional defects which could be reconstructed regardless of localization using numerous plastic-reconstructive procedures with optimal functional and esthetic results. Faster postoperative recovery reduces the costs of the procedure.

We showed in our analysis of surgically treated patients with primary melanoma that plastic surgery has numerous reconstructive capabilities which makes it invaluable in surgical treatment of skin melanoma.

REFERENCES

1. Jemal A, Tiwari RC, Murray T, et al. Cancer statistics. *CA Cancer J Clinics* 2004;54:8-29.
2. Balci CM, Houghton AN, Peters LJ. Cutaneous melanoma. In: De Vita VT, Hellman S, Rosenberg SA, editors. *Cancer: Principles and practice of oncology*, 5th ed. Philadelphia: Lippincott; 1998. p. 1612-61.
3. Healsmith MF, Bourke JF, Osborne JE, et al. An evaluation of the revised seven point check list for the early diagnosis of cutaneous malignant melanoma. *Br J Dermatol* 1994;130(1):48-50.
4. Smolle J, Kaddu S, Kerl H. Non-random spatial association of melanoma and naevi – a morfometric analysis. *Melanoma Res* 1999;9(4):407-12.
5. Gershenwald JE, Sussman JJ, Lee JE. Melanoma. In: Feig BW, Berger DH, Fuhrman GM, editors. *The M.D. Anderson surgical Oncology*, 2nd ed. Houston: Lippincott Williams & Wilkins; 1999. p. 38-68.
6. Retsas S, Henry K, Mohammed MQ, MacRae. Prognostic factors of cutaneous melanoma and new staging system proposed by the American Joint Committee on Cancer (AJCC): validation in a cohort of 1284 patients. *Eur J Cancer* 2002;38:511-26.

7. McCarthy WH, Shaw HM. The surgical treatment of primary melanoma. *Hematol Oncol Clin North Am* 1998;12(4):797-805.
8. Fraker DL. Surgical issues in the management of melanoma. *Curr Opin Oncol* 1997;9(2):183-8.
9. Cascinelli N. Margin of resection in the management of primary melanoma. *Semin Surg Oncol* 1998;14(4):272-5.
10. Hudson DA, Krige JE, Grobbeelaar AO, Morgan B, Grover R. Melanoma in the face: the safety of narrow excision margins. *Scand J Plast Reconst Surg Hand Surg* 1998;32(1):97-104.
11. Johnson TM, Sondak VK. A centimeter here, a centimeter there: does it mater? *J Am Acad Dermatol* 1995;33(3):532-4.
12. Eshima I. The role of plastic surgery in the treatment of malignant melanoma. *Surg Clin North Am* 1996;76(6):1331-42.
13. Ariyan S. Reconstructive surgery in melanoma patients. *Surg Oncol North Am* 1996;5(4):785-807.
14. Panajotović Lj, Kozarski J, Krtnić S, Stanojević B. Plastična hirurgija u lečenju primarnog melanoma. *Vojnosanit Pregl* 2003;60(4):427-33.
15. Cascinelli N, Santinami M. Excision of primary melanoma should allow primary closure of the wound. Recent results. *Cancer Res* 1995;139:317-21.
16. Petro JA, Niaz ZB. Immediate skin expansion: an old concept by a novel and inexpensive technique. *Ann Plast Surg* 1996;36(5):479-84.
17. Narayan D, Ariyan S. Surgical management of the primary melanoma. *Clin Plast Surg* 2000;27(3):409-19.
18. Lent WM, Arizan S. Flap reconstruction following wide local excision for primary malignant melanoma of the head end neck region. *Ann Plast Surg* 1994;33(1):23-7.
19. Papadopoulos T, Rasiah K, Thompson JF, et al. Melanoma of the nose. *Br J Surg* 1997;84(7):986-9.
20. Evans GR, Williams JZ, Ainslie NB. Coetaneous nasal malignancies: is primary reconstruction safe? *Head Neck* 1997;19(3):182-7.
21. Cole DJ, MacKay GJ, Walker BF, et al. Melanoma of the external ear. *J Surg Oncol* 1992;50(2):110-4.
22. Glat PM, Longaker MT, Jelks EB, et al. Periorbital melanocytic lesions: excision and reconstruction in 40 patients. *Plast Reconst Surg* 1998;102(1):19-27.
23. Spinelli HM, Jelks GW. Periocular reconstruction: a systematic approach. *Plast Reconst Surg* 1993;91(6):1017-24.
24. Tseng JF, Tanabe KK, Gadd MA, et al. Surgical management of primary coetaneous melanomas of the hands and feet. *Ann Surg* 1997;225(5):544-50.
25. Evans GR, Friedman J, Shenaq J, Mosser S. Plantar flap reconstruction for acral lentiginous melanoma. *Ann Surg Oncol* 1997;4(7):575-8.
26. Heatton KM, Il-Naggar A, Ensing LG, et al. Surgical management and prognostic factor in patients with subungual melanoma. *Ann Surg* 1994;219(2):197-204.