



Undifferentiated nasopharyngeal carcinoma with isolated central nervous system metastasis

Enis Özyar¹, Gözde Yazici¹, Gaye Tezel², Aysenur Cila³, Osman Ekin Özcan⁴

ABSTRACT

Central nervous system (CNS) metastasis from nasopharyngeal carcinoma is an extremely rare event. Here, we report a case of nasopharyngeal carcinoma with isolated CNS metastases 45 months after the successful treatment of primary tumor.

KEY WORDS: *Nasopharyngeal Neoplasms; Carcinoma; Central Nervous System Neoplasms; Neoplasm Metastasis*

¹Department of Radiation Oncology, ²Department of Pathology, ³Department of Radiology, ⁴Department of Neurosurgery, Hacettepe University, Medical Faculty, Ankara, Turkey; Address correspondence to: Enis Özyar, MD, Department of Radiation Oncology, Hacettepe University, Medical Faculty, 06100 Ankara, Turkey, E-mail: eozyar@hacettepe.edu.tr, The manuscript was received: 19.05.2003, Provisionally accepted: 20.05.2004, Accepted for publication: 20.05.2004

© 2004, Institute of Oncology Sremska Kamenica, Serbia and Montenegro

INTRODUCTION

Nasopharyngeal cancer (NPC) is the head and neck cancer with the highest incidence of distant spread. The commonest distant metastatic sites are reported to be in the bone, lung and liver in descending order, in the literature (1). While intracranial invasion by direct extension from the nasopharynx is a common finding in locally advanced NPC, CNS metastasis of NPC is an extremely rare occurrence (2,3). Moreover, the majority of CNS metastases reported in the literature diagnosed in the spinal cord and commonly occurred as a component of disseminated disease (3-7).

Among 283 non-metastatic NPC patients treated at our department between 1993 and 2002, 52 (18%) developed distant metastasis in 60 sites in the follow up. The sites of distant metastasis included bone in 34 patients, lung in 12 patients, liver in 6 patients, lymph nodes in 4 patients, choroid in 1, and brain in 1 patient. Previously, we reported the case with choroid metastasis, which is also a rare occurrence (8). Here, we present a patient who had isolated CNS metastasis 45 months after successful treatment of primary disease. To the best of our knowledge, the present case is the first case with isolated CNS metastasis from NPC in the English literature.

CASE PRESENTATION

A 41-year-old male was diagnosed with T1N3aM0 - Stage IVB NPC according to the 1997 AJCC Staging System. (9) A magnetic resonance imaging (MRI) scan and fiber optic endoscopy revealed a small primary tumor in nasopharynx and the biopsy revealed undifferentiated carcinoma of the nasopharynx. There was a metastatic lymph node measuring 8 cm in greatest dimension that was palpable in the right neck. Three cycles of cisplatin-based combined chemotherapy regimen (cisplatin, 5-fluorouracil) were given prior to radiotherapy and a complete response was obtained at both primary site and in the neck.

The patient was irradiated with 6 MV photons between August 1999 and September 1999. The nasopharynx and regional lymphatics were treated to a total dose of 59.4 Gy with conventional radiotherapy regimen. Two cycles of cisplatin were given concomitantly with

radiotherapy. After the completion of external radiotherapy, brachytherapy was applied to a total dose of 12 Gy in three fractions. He remained well until 45 months after the conclusion of the radiotherapy, when he was admitted to the hospital with the complaints of drowsiness and fainting spells. On MR imaging, there was an irregularly thickened leptomeningeal mass enhanced intensely with Gd-DTPA (Figure 1a, b) and enhancement continued into the petrous bone. The mass incited considerable edema in the adjacent brain parenchyma (Figure 1c).

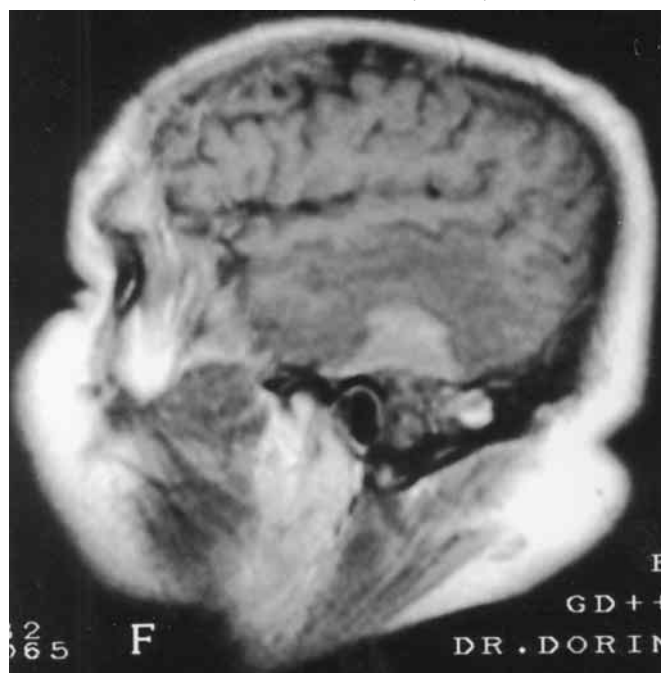


Figure 1a. Postcontrast sagittal T1 weighted SE image shows homogenously enhancing extraaxial mass and adjacent edema in the right temporal lobe

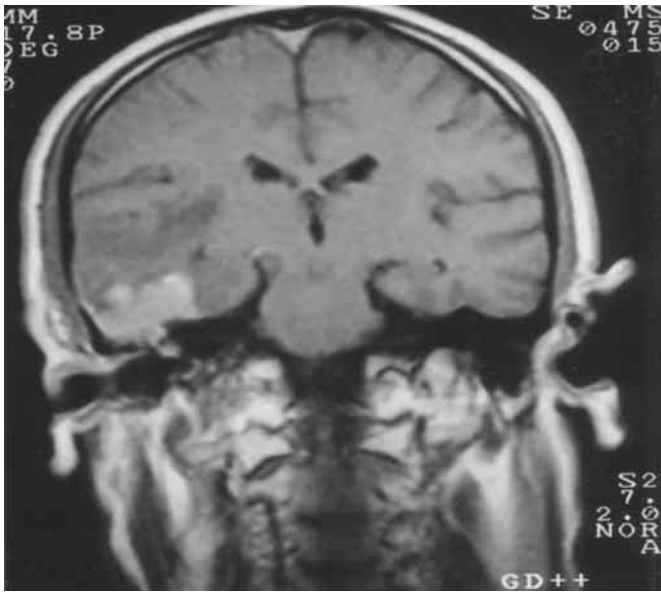


Figure 1b. Postcontrast coronal T1-weighted SE image demonstrates the enhancement in right mastoid antrum mass in continuity with leptomeningeal mass

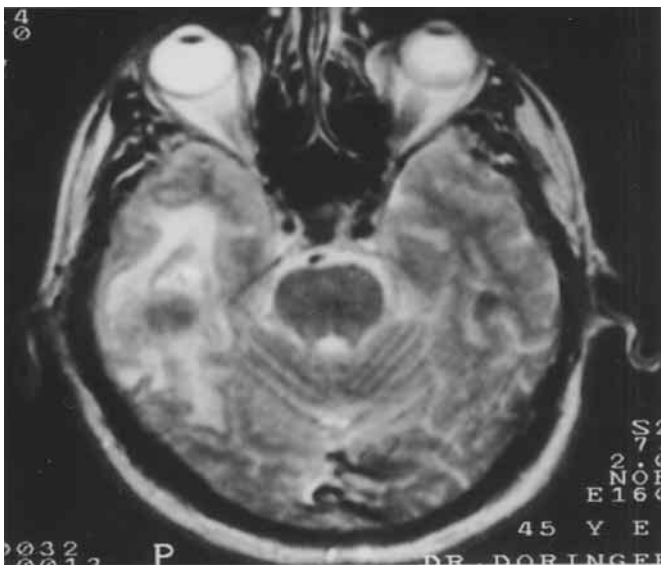


Figure 1c. T2-weighted axial image shows the mass is hypointense relative to the gray matter and edema is hyperintense around the mass

Radiologically, it was thought to be a slow infection of mastoid air cells that involved leptomeningeal of middle cranial fossa. The brain lesion was excised totally with a craniotomy and pathological examination revealed metastatic undifferentiated carcinoma. On microscopic examination, the tumor consisted of well-defined islets of epithelial cells surrounded by fibrous tissue and moderate lymphoid cells. The tumor was highly cellular and composed of pleomorphic cells with eosinophilic cytoplasm and single prominent nucleoli. There were focal necrosis, apoptosis foci, and high mitosis. Immunohistochemical study revealed that the tumor cells showed membranous EMA (epithelial membrane antigen) immunoreactivity. On the other hand, GFAP positivity was limited to reactive astrocytes (Figure 2a, b).

Original diagnosis of the nasopharyngeal mass made in 1997 was confirmed to be undifferentiated nasopharyngeal carcinoma, which has similar morphological characteristics as the metastatic carcinoma to the brain. No other metastatic lesion was detected in the systemic workup. The patient was treated with whole brain radiotherapy to a total dose of 3000 cGy in 10 fractions.

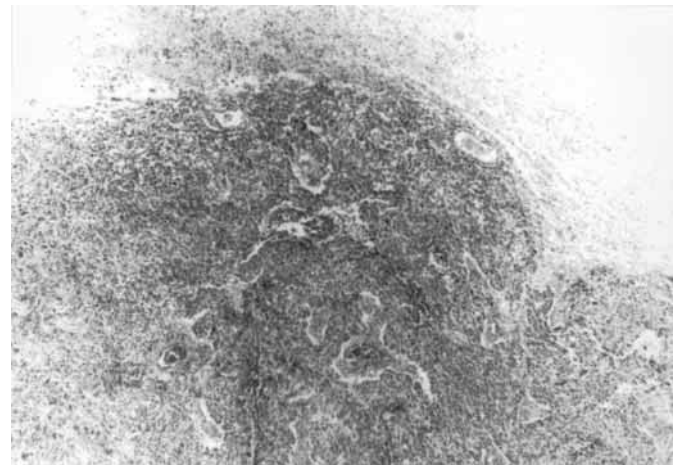


Figure 2a. Metastatic carcinoma in the brain. Tumour cells surrounded by fibrous tissue (Original magnification HEX40). Note the pleomorphic cells with abundant cytoplasm (b) (Original magnification HEX400)

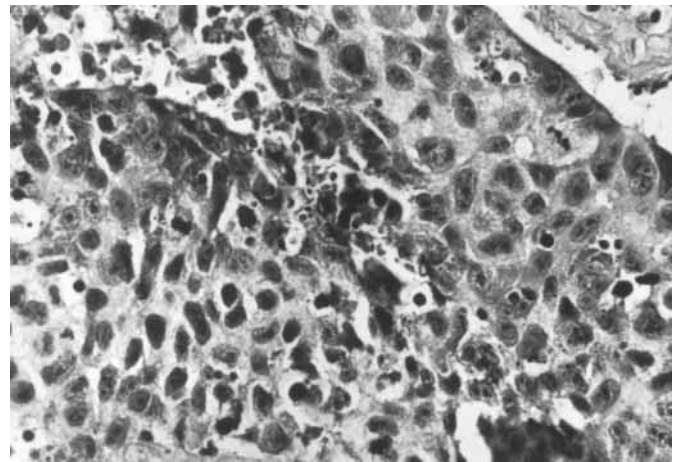


Figure 2b. Metastatic carcinoma in the brain. Note the pleomorphic cells with abundant cytoplasm (Original magnification HEX400)

DISCUSSION

Though intracranial invasion by direct extension of locally advanced disease is not uncommon, metastases to the CNS, either through hematogenous route or through the cerebrospinal fluid (CSF), from NPC have rarely been reported (3,10). There have been several case reports of spinal cord metastases, all of which associated with locally advanced disease (3-7). The possible mechanism of metastases was hypothesized to be dissemination through CSF. In the two patients with brain metastases mentioned in the literature, widespread systemic metastases were also reported (3,10). The present case was the first to present with isolated CNS metastasis of a NPC with T1 primary tumor. Since the blood brain barrier is not anticipated to be disrupted at this early stage of illness and no local recurrence was observed, hematogenous route rather than dissemination through CSF is considered to be the possible mechanism. In the above-mentioned two case reports, metastatic lesions have been reported to be located in the occipital lobes (3,10). In the present case, metastatic lesion was located in the temporal lobe. There is no known lymphatic or vascular connection between the nasopharynx and temporal lobes. Ngan and colleagues, discussing the same issue for the patients who had occipital metastases, hypothesized that microenvironment in the occipital lobes might have facilitated the metastatic tumor cells to localize in that region. The present case has shown that the occipital lobes are not the only sites for NPC cells to metastasize. Distant metastasis to only one organ/site has been reported to be related to favorable prognosis independent of the number of metastases (1). Status

of primary tumor, evidences of disseminated disease, performance status of the patient, treatment modalities already applied to the patient, histopathology of the tumor, and symptoms related to brain metastases are factors effecting the therapeutic management. It is important to mention that NPC patients with CNS metastasis in the literature had had pulmonary and liver metastasis before developing CNS metastases. (3,5,6,10) This association suggests the hematogenous route of occurrence in majority of metastases of the CNS. As all of the patients with metastasis to the brain have accompanying widespread systemic disease, systemic therapy can be a good treatment option affecting all metastatic disease in the body. But the chance of effect from further systemic therapy is limited, as most of the patients have already been treated with chemotherapy. Since there was no locoregional recurrence when the patient presented with isolated CNS metastasis, total excision of the metastatic tumor and postoperative radiotherapy were planned to gain a better survival.

REFERENCES

1. Teo PM, Kwan WH, Lee WY, Leung SF, Johnson PJ. Prognosticators determining survival subsequent to distant metastasis from nasopharyngeal carcinoma. *Cancer* 1996;77:2423-31.
2. Ozyar E, Atahan IL, Akyol FH, Gurkaynak M, Zorlu AF. Cranial nerve involvement in nasopharyngeal carcinoma: Its prognostic role and response to radiotherapy. *Radiation Med* 1994;12:65-8.
3. Ngan RKC, Yiu HHY, Cheng HKM, Chan JKC, Sin V, Lau W. Central nervous system metastasis from nasopharyngeal carcinoma. A report of two patients and review of the literature. *Cancer* 2002;94:398-405.
4. Elango S, Kareem BA, Chandrasekaran S, Azman N. Intramedullary cervical cord metastasis from a nasopharynx carcinoma. *Eur Neurol* 1974;11:317-22.
5. Lee C, Chan AT, Teo PM, Chan YL. Intramedullary metastases in nasopharyngeal carcinoma. *Oncol Forum* 1999;3:7-9.
6. Lii FN, Chen YM, Shu CH, Liu JM, Whang-Peng J. Metastatic nasopharyngeal carcinoma with epidural spinal cord compression: report of an unusual and catastrophic event. *Zhonghua Yi Xue Za Zhi (Taipei)* 1995;55:195-8.
7. Morariu MA, Serban M. Intramedullary cervical cord metastasis from a nasopharynx carcinoma. *Eur Neurol* 1974;11:317-22.
8. Ozyar E, Kiratli H, Akbulut S, Uzal D, Atahan IL. Choroid metastasis of undifferentiated nasopharyngeal carcinoma. *J Laryngol Otol* 1998;112:667-9.
9. Ozyar E, Yildiz F, Akyol FH, Atahan IL. Comparison of AJCC 1988 and 1997 classifications for nasopharyngeal carcinoma. *Int J Radiat Oncol Biol Phys* 1999;44:1079-88.
10. Liaw CC, Ho YS, Koon-Kwan NG, Chen TL, Tzann WC. Nasopharyngeal carcinoma with brain metastasis: a case report. *J Neurooncol* 1994;22:227-30.