

Srdan MILENKOVIĆ¹

I. BERISAVAC²

Dubravka CVETKOVIĆ-DOŽIĆ³

I. BERISAVAC⁴

¹DEPARTMENT OF HISTOPATHOLOGY, CHC ZEMUN-BELGRADE, SERBIA AND MONTENEGRO

²DEPARTMENT OF NEUROSURGERY, CHC ZEMUN-BELGRADE, SERBIA AND MONTENEGRO

³INSTITUTE OF PATHOLOGY, MEDICAL SCHOOL BELGRADE, SERBIA AND MONTENEGRO

⁴INSTITUTE OF NEUROLOGY, CLINICAL CENTRE OF SERBIA, BELGRADE, SERBIA AND MONTENEGRO

Meningiomas - true dependent tumors?

KEYWORDS: Meningioma; Immunohistochemistry; Receptors, Estrogen; Receptors, Progesterone

ABSTRACT

Steroid hormones are involved in various aspects of growth, development, differentiation, and reproduction. The development of two major cancers breast and prostate is affected by hormones in the body, as well as some sarcomas. Although they do not arising from a tissue normally thought to be a target tissue for estrogen and progesterone, meningiomas show a number of epidemiological and clinical features which suggest that female sex hormones can play a role in their development. We investigated the sex hormone receptor content of benign meningiomas (WHO grade I), which is completely excised (Simpson graded I) by immunohistochemical methods. All of 30 (100%) tumor samples were estrogen negative. Seventeen (57%) of all tumor samples were positive for progesterone receptors. The mean concentration of progesterone receptors in the group of male patients was high (with $p < 0.05$) as that in the group female patients. The present work offers data that may support the use of endocrine treatment for a recurrent or incompletely excised benign meningiomas male patients.

INTRODUCTION

Pivotal experiments performed in the late 1950s and early 1960s, primarily in the laboratories of Gerald Mueller and Elwood Jensen. Jensen's laboratory showed that tritiated estradiol was specifically taken up and retained in the immature rat uterus, indicating the presence of an "estrogen-binding component" or "estrophilin," later termed "estrogen receptor" by Jensen (1,2). For many years, it was thought that ER bound estrogen in the cytoplasm and was then translocated to the nucleus. However, it is now known that ER is a nuclear factor that initiates interaction with estrogen in the nucleus. (3.) The same holds true for PR, although other members of the steroid/thyroid hormone receptor superfamily appear to have both nuclear and cytoplasmic localization (4).

In 1972, O'Malley's laboratory was the first to purify a steroid hormone recep-

tor, PR from chicken, to near homogeneity. Interestingly, they discovered two isoforms, PR-A and PR-B. PR-B is 100 amino acids longer (NH₂ terminus) than PR-A, but otherwise the two isoforms are identical. This finding is consistent between species, with the exception of rabbit, in which PR exists as a single form (5). Soon after the purification of PR, ER and AR were purified, although it was not until 1996 that second form of ER, ER-B, was discovered (6,7). Shortly after this milestone, the receptors for estrogen (1986), now known to be ER-A, progesterone (1987), and androgen (1988) were cloned. In humans, the ER-A gene resides on chromosome 6, where as ER-B is on chromosome 14. Human PR localizes to chromosome 11 and the AR gene resides on the X chromosome, underscoring its necessity for female, as well as male, development (6,8,9).

Cloning of PR also allowed for the understanding of how the A and B isoforms are derived from the same gene. Interestingly, different species accomplish this feat via different methods, with the chicken isoforms arising as a result of different translation start sites within the same transcript, and the human isoforms occurring via different transcription start sites (5). In vitro experiments performed in the mid 1990s demonstrated that receptor binding to DNA is not hormone dependent. Experiments performed by the Pratt and Toft laboratories in the late 1980s demonstrated that the dissociation of HSPs from receptors is hormone-dependent (10,11).

In the mid 1980s, steroid hormone receptors were shown to be phosphorylated in a hormone-dependent manner. Edwin Milgrom's laboratory showed that PR is phosphorylated, and with hormone administration, becomes hyperphosphorylated (5). These experiments suggested that steroid hormone receptor action is dependent on phosphorylation status. These discoveries were the culmination of the previous three decades of research and led to a well-supported model for steroid hormone receptor action: ligand binding induces a conformational change in the receptor, releasing heat shock protein-HSPs. The receptor undergoes hormone and DNA-dependent hyperphosphorylation, dimerizes, and binds its target DNA. The binding of the receptor to the SRE allows for the recruitment of general transcription factors and, subsequently, RNA polymerase to begin efficient transcription (5,12).

Despite the great deal of information about steroid hormone action now known, many questions remain unanswered relating to receptor activation, regulation, and protein interactions. Since the early 1990s, it has been known that ligand-independent activation of PR and ER can occur. However, the full implications of these observations are not yet understood, although researchers have suggested that this type of activation may be associated with breast and uterine cancers.

Yet another question deserving of further attention is how rapid cellular responses to steroid hormones, which cannot be explained by classic hormone transactivation, occur. This "nongenomic" mechanism was proposed as early as 1975 by Richard Pietras and Clara Szego to involve membrane-bound steroid receptor-induced increases in intracellular second messengers (13,14).

Steroid hormones are involved in various aspects of growth, development, differentiation, reproduction, and homeostasis. They exert their effects by means of steroid hormone receptors, such as estrogen (ER), progesterone (PR), androgen (AR), glucocorticoid (GR), and mineralocorticoid receptors. Steroid hormone receptors belong to the steroid/thyroid hormone receptor superfamily, which includes thyroid hormone (TR), retinoic acid (RAR), and vitamin D₃ receptors, as well as "orphan" receptors [e.g., ER-related-1 (ERR-1), ERR-2, and chicken ovalbumin upstream promoter-transcription factor], for which no ligands have yet been found. All members of the steroid and thyroid hormone receptor superfamily share similar structure consisting of modular domains from A to F (from NH₂ to COOH terminus (15)). Each receptor contains a unique A/B region, which is variable in length and sequence between the receptors.

The A/B region allows for protein-protein interactions and transcriptional activation of target genes. The cysteine-rich C region is important for DNA binding and receptor dimerization. In some receptors, region D contains the

Address correspondence to:
Dr. Sanja Milenković, KBC Zemun, Dept. of Clinical Histopathology, 11080 Zemun, Vukova 9, Serbia and Montenegro

The manuscript was received: 15. 02. 2004.

Provisionally accepted: 15.03.2004.

Accepted for publication: 23.03.2004.

nuclear localization signal and/or a transactivation domain. The E region is responsible for several functions, including ligand binding, heat shock protein (HSP) association, receptor dimerization, nuclear localization, hormone-dependent transactivation, and, in some cases, transcriptional repression. The F region is present in few receptors and exhibits minimal regulatory function (15).

In addition to the direct contact with the basal transcription machinery, nuclear receptors enhance or suppress transcription by recruiting an array of coactivators and corepressors, collectively named coregulators. Therefore, the mutation or aberrant expression of sex steroid receptor coregulators will affect the normal function of the sex steroid receptors and hence may participate in the development and progression of the cancers (16). The development of two major cancers breast and prostate is affected by hormones in the body, as well as some sarcomas.

The meninges develop from cells of the neural crest and mesenchyme (mesoderm), which migrate to surround the developing central nervous system (17,18). Although they do not arise from a tissue normally thought to be a target tissue for estrogen and progesterone, meningiomas show a number of epidemiological and clinical features which suggest that female sex hormones can play a role in their development. For example, higher incidence of meningiomas is in women and are rarely diagnosed before puberty or during the senium, corresponding to the time of maximal gonadal activity (19,20). Meningiomas have been documented clinically and radiologically to undergo relatively rapid expansion during pregnancy, followed by spontaneous regression postpartum (21-23). Some women suffer exacerbations of symptoms in the luteal phase of the menstrual cycle. These fluctuations in tumor size have been attributed to steroid-induced increased vascular engorgement of the tumor, or direct trophic effects of gonadal hormones on meningioma cells (24-26). Meningiomas are more common in obese women (26) and in patients with hormone-dependent breast carcinoma (27,28). The greater prevalence of these tumors in obese individuals may be related to higher circulating estrogen levels derived from the aromatization of androstenedione to estrone in adipocytes (29).

Numerous investigators have demonstrated the presence of PR and, to a lesser extent, ER in a significant number of human meningioma specimens (30). These observations suggest that progestins and possibly other gonadal steroids may directly modify the growth and differentiation of meningiomas. The presence of progestin receptors may indicate a more favorable prognosis because progesterone receptor-negative meningiomas have been associated with a greater tendency for brain invasiveness, higher mitotic indices and necrosis and shorter disease-free intervals (31,32).

In an early study, the antiestrogen tamoxifen did not appreciably affect tumor size or neurological status in patients with inoperable meningiomas (33). On the other hand, the antiprogestin mifepriston (RU486) has been reported to induce stabilization or regression of meningiomas in a cohort of patients, suggesting that antiprogestone therapy may be useful in the management of these tumors (34). However, the effects of progestins and mifepristone on meningioma growth in vitro are contradictory (35-37).

The aim of our study was to investigate the sex hormone receptor content of benign meningiomas (WHO grade I), which is completely excised (Simpson gradus I) by immunohistochemical methods and evaluate possible relationship between receptor content and the gender and older patients, histological type of meningiomas and localization of tumors.

MATERIAL AND METHODS

Surgical specimens were obtained from thirty (30) consecutively treated patients with intracranial meningiomas operated in the Department of Neurosurgery CHC Zemun during the 2001/2002 year. Tissue samples of meningiomas were obtained from peripheral area of the tumors with nonheat-producing instruments, necrosis and bleeding. All of tumors operated in toto (Simpson gradus I). Tumor tissue was fixed in formalin and embedded in

paraffin by standard methods. Section (5nm) were stained with Hematoxylin and Eosin, Periodic Acid Schiff and Gordon Sweett reticulin. Tumors were classified according to the new classification system of the WHO (World Health Organization), as a benign WHO grade I.

For progesterone and estrogen immunostaining, tissue sections of formalin fixed, paraffin embedded surgical specimens were deparaffinized in xylene and processed through two changes of absolute ethanol. Sections were rehydrated through an ethanol series and briefly soaked on phosphate buffered saline. The endogenous peroxidase activity was blocked with 0,3% H₂O₂ for 10 minutes. Tissue sections were then microwaved as follows: slides were placed in a thermo resistant plastic jar with 10 mM citrate buffer and microwaved at high power (700W) for 203 minutes until the solution came to rapid boil. The oven was then reset at 55% power and heating was continued for 7-8 minutes to maintain gentle boil, with stops every 2 minutes to replace lost liquid. Slides were then allowed to cool for 20-30 minutes on the room temperature, and rinsed with several changes of distilled water before proceeding with the immunostaining. Nonspecific reaction were blocked by incubating the sections with blocking reagents (Biotin blocking System, DAKO Co. No.X0901). Tissue section were then incubated with anti-progesterone monoclonal antibody (mouse anti-human progesterone receptor DAKO Co.No.1595) and anti-estrogen monoclonal antibody (mouse anti human estrogen receptor DAKO Co.No.1575). Then the sections were incubated with biotin-labeled secondary antibody and the avidin-biotin-peroxidase complex, one hour each step, with washing in PBS between steps. Sections of tissue fibroadenoma gll. mammae used as a positive and negative control.

All slides were determined by numbers positively stained tumor cells nuclei in the 10 high power fields (400X). The PR and ER score were analyzed against patients' gender, age and histological subtype of the tumor. The correlation between number of positively nuclei and PR and ER status was determined by the analytic statistical test Mann Whitney.

RESULTS AND DISCUSSION

The patient group consisted of 13 men and 17 women with a mean age of 48.7 years (SD-standard error 13.5 years). Based on the WHO criteria intracranial meningiomas were classified as fibroblastic 12 (40%), meningothelial 8 (26.67%), transitional 3 (10%), angiomatous 2 (6.67%), psammomatous 2 (6.67%), metaplastic 2 (6.67%) and secretory types 1 (3.33%). Seven tumor were located in the parasagittal regions, 6 in the falcial regions, 5 in the baseos crani anterior, 5 in the regio temporalis, 3 in the baseos crani posterior, 3 in the regio frontalis and 1 in the regio occipitalis. All of 30 (100%) tumor samples were estrogen negative. Seventeen (57%) of all tumor samples were positive for progesterone receptor (Figure1). Positive staining for progesterone receptors was restricted to the tumor cell nuclei and no reaction was observed in the tumor cell cytoplasm, in connective tissue and endothelial cells.

We found that 8 of 17 (47.05%) tumors in women had progesterone receptors and 9 of 13 (69.23%) tumors in males had progesterone receptors.

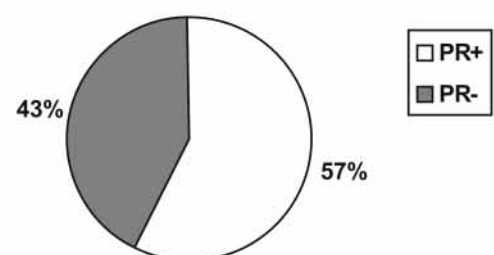


Figure 1. PR expression in benign meningiomas

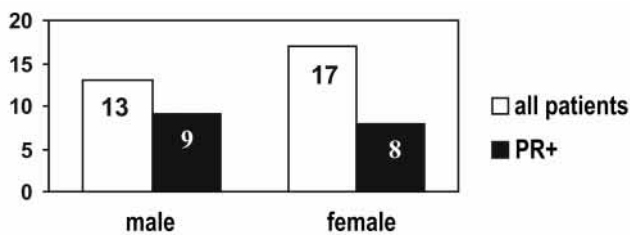


Figure 2. PR expression in male and female patients

The mean concentration of progesterone receptors in the group of male patients was high (with $p < 0.05$) as that in the group female patients (Figure 2). We found that age, location of tumor and histological subtype did not correlate with PR status.

Breast fibroadenoma tissue that had been stained for either the PR or ER acted as a positive control and stained strong and unequivocal nuclear immunoreactivity. For use as a negative control, substitution of primary antibody with preimmune serum completely abolished the immunostaining.

In breast cancers, estrogen (ER) and progesterone (PR) receptors control tumor development and growth, they are markers of hormone dependence and tumor aggressiveness, and they are targets for treatments with antiestrogens, aromatase inhibitors and progestins. In hormone-dependent breast cancer, the tumor cells have estrogen receptors (ER positive tumors) and need estrogen to grow. Although progesterone had no effect on growth in the control transfectant, the hormone markedly inhibited DNA synthesis and cell growth. This growth inhibition was associated with an arrest of cells in the G_0/G_1 phase of the cell cycle (38). Absence of PR expression in primary breast cancer is associated with disease progression and may be a marker of an aggressive tumour phenotype (39). In ER- tumors, the PgR status was significantly related to: age, menopausal status, tumor size, SBR grade, and histological type (40).

Tamoxifen and anti-estrogens like tamoxifen compete with estrogen for binding to estrogen receptors, thus blocking tumor growth stimulated by estrogen. However, with uterine tissue, the tamoxifen-receptor complex might stimulate endometrial and endometrial tumor growth (41). The new generation of potent steroidal and nonsteroidal inhibitors of the enzyme aromatase act by decreasing estrogen production throughout the body in postmenopausal women. Three new aromatase inhibitors are: anastrozole (ARIMIDEX) letrozole (FEMARA), and vorozole (RIVIZOR) (42-44).

Androgen plays a critical role in the promotion and growth of prostate cancer. Anti-hormonotherapy includes suppressing the release of male hormones using high doses of female hormones (estrogens), hormone-suppressing drugs, and anti-androgens to block androgen receptors. androgen induced blockade of caspase activation in both intrinsic and extrinsic cell death pathways and thereby was able to protect prostate cancer cells from androgen blocks apoptosis of hormone-dependent prostate cancer cells (45).

Liposarcomas (43%) and leiomyosarcomas (60%) had a high incidence of estrogen receptor. In contrast, sarcomas of fibrous and synovial tissue origin lacked any detectable receptor for estrogen. Malignant fibrous histiocytoma had the highest incidence of glucocorticoid (66%) and androgen (66%) receptors. The incidence of receptors for estrogen and glucocorticoid was higher in female than in male patients (62% and 38%, respectively) (46).

Usually meningiomas are considered to be benign and are associated with a relatively good prognosis (47,48). It has recently been established that atypical and anaplastic meningiomas exhibit an overall increased rate of recurrence, even after gross total resective. However, recurrence of meningiomas is not restricted to the aggressive type, because histologically benign meningiomas may also recur and have 10-year regrowth rate of 15%-20% (47-49). Estrogen receptors, progesterone receptors and their participation in the growth of human meningiomas have been extensively analyzed by many recent studies. However, there are numerous discrepancies in the literature among the results for estrogen receptor (ER), with some groups claiming estrogen

receptors are present, while other groups have not found them (50-53). The biological function of sex hormones in meningiomas and their molecular basis are still unknown.

PR and ER have not a relationship in meningiomas as well as in case of the carcinoma glandulae mammae. Despite variations in results it is generally agreed that the majority of meningiomas possess the PR but devoid of the ER (50). We investigated the expression of PR and ER in 30 cases of benign completely excised meningiomas. In our studies 56% of the 30 tumors samples showed PR expression. We demonstrated a sex difference in the expression of PR and the higher percentage of male with meningiomas have progesterone expression than the women. We found that 9 of 13 (69%) tumors in man had PR; in contrast only 8 of 17 (35%) tumors in women. Other studies have not found a positive correlation between male sex of patients, but some studies which analyzed malignant as well as atypical and benign meningiomas, showed that the expression PR was higher in women (54). Our data are agreement with general consensus in the literature that patient age, localization of the tumor and histological subtype of the benign meningiomas do not correlate with PR status (51-53).

Although gender alone was not a significant factor, there was in our studies, a higher proportion ($p > 0.05$) male patients with positive PR. The presence of nuclear PR in tumor cells provides a benign form of tumors male patients.

CONCLUSION

The present work offers data that may support the use of endocrine treatment for a recidivism or incompletely excised benign meningiomas male patients.

REFERENCES

- Jensen EV, Greene GL, Closs LE, DeSombre ER, Nadj M. Receptors reconsidered: a 20-year perspective. *Recent Prog Horm Res* 1982;38:1-40.
- O'Malley BW. Thirty years of steroid hormone action: personal recollections of an investigator. *Steroids* 1995;60:490-8.
- MacGregor JI, Jordan CV. Basic guide to the mechanisms of antiestrogen action. *Pharmacol Rev* 1998;50:151-96.
- DeFranco DB. Regulation of steroid receptor subcellular trafficking. *Cell Biochem Biophys* 1999;30:1-24.
- Savouret JF, Chauchereau A, Misrahi M, Lescop P, Mantel A, Bailly A et al. The progesterone receptor. Biological effects of progestins and antiprogestins. *Hum Reprod* 1994;(Supp9)1:7-11.
- Gustafsson JA. An update on estrogen receptors. *Semin Perinatol* 2000;24:66-9.
- Mosselman S, Polman J, Dijkema R. ER beta: identification and characterization of a novel human estrogen receptor. *FEBS Lett* 1996;392:49-53.
- Law ML, Kao FT, Wei Q, Hartz JA, Greene GL, Zarucki-Schulz T et al. The progesterone receptor gene maps to human chromosome band 11q13, the site of the mammary oncogene int-2. *Proc Natl Acad Sci USA* 2000;84:2877-81.
- Prins GS. Molecular biology of the androgen receptor. *Mayo Clin Proc* 2000;Suppl:S32-S35.
- Metzger D, Berry M, Ali S, Chambon P. Effect of antagonists on DNA binding properties of the human estrogen receptor in vitro and in vivo. *Mol Endocrinol* 1995;9:579-91.
- Sanchez ER, Meshinchi S, Tienrunroj W, Schlesinger MJ, Toft DO, Pratt WB. Relationship of the 90-kDa murine heat shock protein to the untransformed and transformed states of the L cell glucocorticoid receptor. *J Biol Chem* 1987;262:6986-91.
- Jensen EV. Steroid hormones, receptors, and antagonists. *Ann NY Acad Sci* 1996;784:1-17.
- Katzenellenbogen BS. Mechanisms of action and cross-talk between estrogen receptor and progesterone receptor pathways. *J Soc Gynecol Invest* 2000;7:S33-S37.
- Schmidt BM, Gerdes D, Feuring M, Falkenstein E, Christ M, Wehling M. Rapid, nongenomic steroid actions: A new age? *Front Neuroendocrinol* 2000;21:57-94.
- Shibata H, Spencer TE, Onate SA, Jenster G, Tsai SY, Tsai MJ et al. Role of co-activators and co-repressors in the mechanism of steroid/thyroid receptor action. *Recent Prog Horm Res* 1997;52:141-64.
- Xiuhua G, Loggie BW, Nawaz Z. The roles of sex steroid receptor coregulators in cancer. *Mol Cancer* 2002;1(1):7-10.
- Kepes JJ. Meningiomas. Biology, pathology and differential diagnosis. New York: Masson Publishing U.S.A., Inc; 1982.

18. Williams PL, editor. *Grays Anatomy*, 38th ed. New York: Churchill Livingstone; 1995.
19. Schoenberg BS. Nervous system. In: Schottenfeld D, Fraumeni JF, editors. *Cancer Epidemiology and Prevention*. Philadelphia: WB Saunders; 1982. p. 968.
20. Poisson M. Sex steroid receptors in human meningiomas. *Clin Neuropharmacol* 1984;7:320-4.
21. Michelsen JJ. Brain tumor and pregnancy. *J Neurol Neurosurg Psychiatry* 1969;32:305-7.
22. Bickerstaff ER, Small FY, Guest JA. The relapsing course of certain meningiomas in relation to pregnancy and menstruation. *J Neurol Neurosurg Psychiatry* 1968;21:84-91.
23. Haddad G, Haddad F, Worseley K, Villemure JG. Brain tumours and pregnancy. *Can J Neurol Sci* 1991;18:231-6.
24. Schoenberg BS. Nervous system. In: Schottenfeld D, Fraumeni JF, editors. *Cancer Epidemiology and Prevention*. Philadelphia: WB Saunders; 1982. p. 968.
25. Chaudhuri P, Wallenburn HSC. Brain tumours and pregnancy. *Eur J Obstet Gynecol Reprod Biol* 1980;11:109-13.
26. Bellur S, Chandra V, Anderson R. Association of meningiomas with obesity. *Ann Neurol* 1983;13:346-57.
27. Miller RE. Breast cancer and meningiomas. *J Surg Oncol* 1986;31:182-3.
28. Schoenberg G, Christine B, Whisnant J. Nervous system neoplasms and primary malignancies of other sites: the unique association between meningiomas and breast cancer. *Neurology* 1975;25:705-10.
29. Kirschner M, Schneider G, Ertel N. Obesity, androgens, estrogens and cancer risk. *Cancer Res* 1982;42:3281-7.
30. Schipper HM. Neurology of sex steroids and oral contraceptives. *J Neurol Clin* 1986;4:721-6.
31. Hilbig A, Barbosa-Coutinho LM. Meningiomas and hormonal receptors: immunohistochemical study in typical and non-typical tumors. *Arquiv Neuro-Psiquiatria* 1998;56:193-6.
32. Hsu DW, Efid JT, Hedley-Whyte ET. Progesterone and estrogen receptors in meningiomas: prognostic considerations. *J Neurosurg* 1997;86:113-21.
33. Markwalder TM, Seiler RW, Zava DT. Endocrine manipulation of inoperable and recurrent meningiomas - a pilot study. In: Spitzky K, Karrer K, editors. *Proceedings of the 13th International Congress of Chemotherapy*. Egermann, Vienna; 1983.
34. Lamberts SWJ, Tanghe HLJ, Avezaat CJJ et al. Mifepristone (RU 486) treatment of meningiomas. *J Neurol Neurosurg Psychiatry* 1992;55:486-91.
35. Blankenstein MA, Van der Meulen-Dijk C, Thijssen JHH. Effect of steroids and antisteroids on human meningioma cells in primary culture. *J Steroid Biochem* 1989;34:419-25.
36. Maiuri F, Montagnani S, Gallicchio B et al. Oestrogen and progesterone sensitivity in cultured meningioma cells. *Neurol Res* 1989;11:9-13.
37. Adams EF, Schrell UMH, Fahlbusch R, Thierauf P. Hormonal dependency of cerebral meningiomas. Part 2. In vitro effect of steroids, bromocriptine, and epidermal growth factor on growth of meningiomas. *J Neurosurg* 1990;73:750-6.
38. Lin VC et al. Progesterone inhibits the growth of MDA-MB-231 cells transfected with progesterone receptor complementary DNA. *Clin. Cancer Res* 1999;5:395-403.
39. Balleine RL et al. Absence of progesterone receptor associated with secondary breast cancer in postmenopausal women. *Br J Cancer* 1999;79:1564-71.
40. Bernoux A. Estrogen receptor negative and progesterone receptor positive primary breast cancer: pathological characteristics and clinical outcome. Institut Curie Breast Cancer Study Group. *Breast Cancer Res Treat* 1998;49:219-25.
41. Kerbrat P, Lefevre C. Aromatase inhibitors: a review of clinical trials. *Bull Cancer* 2000;87:31-9.
42. Gan T. Development of a novel aromatase inhibitor, anastrozole (Arimidex) - its basic and clinical studies. *Kagaku Ryoho* 2001;28(4):549-60.
43. Casali JA, Sega FM, Giuntini T, Casali M, Cappellini GC, Terzoli E. Letrozole for the treatment of pretreated advanced breast cancer patients: preliminary report. *Exp Clin Cancer Res* 2000;19(1):915-7.
44. Hamilton A. The third-generation non-steroidal aromatase inhibitors: a review of their clinical benefits in the second-line hormonal treatment of advanced breast cancer. *Ann Oncol* 1999;10(4):377-84.
45. Kimura K, Markows M. Androgen Blocks Apoptosis of Hormone-dependent Prostate Cancer Cells. *Cancer Res* 2001;61:7544-51.
46. Chaudhuri PK, Walker MJ, Beattie CW, Das Gupta TK. Distribution of steroid hormone receptors in human soft tissue sarcomas. *Surgery* 1981;90(2):149-53.
47. Louis DN, Scheithauer BW, Budka H, Demling A, Kepes JJ. Meningiomas. In: Kleihues P, Cavene WK, editors. *Tumours of the Nervous System: Pathology & Genetics: World Health Organization International Classification of Tumors*. Lyon: IARC Press; 2000. p. 176-84.
48. Bruner JM, Tien RD, Enterline DS. Tumors of the meninges and related tissues. In: Bigner DD, Mc Lendon RE, Bruner JM, editors. *Russell and Rubinstein's Pathology of Tumors of the Nervous System*, 6th ed. London: Arnold; 1998:67-139.
49. Schnitt JS, Vogel H. Meningiomas: diagnostic value of immunoperoxidase stainings for Epithelial Membrane Antigen. *Am J Surg Path* 1986;10(9):640-9.
50. Hsu WD, Efid JT, Hedley-Whyte ET. Progesterone and Estrogen receptor in meningiomas: prognostic considerations. *J Neurosurg* 1997;86:113-20.
51. Rubinstein AB, Loven D, Geier A, Reichenthal E, Gadoth N. Hormone receptors in initially excised versus recurrent intracranial meningiomas. *J Neurosurg* 1994;81:184-7.
52. Fewings PE, Battersby RDE, Timperley WR. Long-term follow up of progesterone receptors status benign meningioma: prognostic indicator of recurrence? *J Neurosurg* 2000;92:401-5.
53. Assimakopoulou M. Human meningioma: Immunohistochemical localization of progesterone receptor and heat shock protein 27 and absence of estrogen receptor and PS2. *Cancer Detect Prev* 2000;24(2):163-8.
54. Carroll RS, Glowacka D, Dashner K. Progesterone receptor expression in meningiomas. *Cancer Res* 1993;53:1312-6.