



# Gestational trophoblastic disease

**Milica ŽIVALJEVIĆ**  
**Marija TEŠIĆ**  
**Tamara VUJKOV**  
**Jelka RAJOVIĆ**  
**Marina POPOVIĆ**

*Gestational trophoblastic disease belongs to a spectrum of rare tumors originating from trophoblast. It spreads from the benign disease - uncomplicated partial mole to the most malignant choriocarcinoma in stage IV of disease with brain metastases. Fortunately, with adequate chemotherapy, even patients in advanced stage of the disease have significant chances to be cured. In estimating prognosis and adequate therapy of disease, the most significant are clinical factors: serum  $\beta$ hCG level, duration of the disease from termination of antecedent pregnancy, prior chemotherapy, brain or liver metastases.  $\beta$ hCG is an ideal tumor marker for follow up and early diagnosis of recidivism and metastases. In the Institute of Oncology in Sremska Kamenica 32 patients with gestational trophoblastic disease were treated in the period from 1987 to 2001. All the patients with non-metastatic disease and low risk metastatic disease (stage I-III FIGO) were successfully cured. Five patients died, all in stage IV of the disease (FIGO) with liver and brain metastases; in 4 of them disease occurred after term pregnancy. Overall survival was 85%. Treatment of non-metastatic and low risk metastatic disease was successful in all cases. Treatment failures occurred in advanced disease with brain and liver metastasis. Specificity and low incidence of this disease ask for the treatment to be carried out in specialized centers, as it is in developed countries (Trophoblastic Disease Centers).*

**KEY WORDS:** *Trophoblastic Neoplasms; Choriocarcinoma; Risk factors; Antineoplastic Combined Chemotherapy Protocols; Treatment Outcome*

*Archive of Oncology 2002,10(2):71-75©2002,Institute of Oncology Sremska Kamenica, Yugoslavia*

INSTITUTE OF ONCOLOGY SREMSKA KAMENICA,  
SREMSKA KAMENICA, YUGOSLAVIA

## INTRODUCTION

**G**estational trophoblastic disease includes following forms of growth disturbance of the human trophoblast: hydatiform mole, invasive mole, choriocarcinoma and placental site trophoblastic tumors. Term gestational trophoblastic disease is applied to the latter three conditions. Diagnosis and decision to institute treatment are sometimes undertaken without histopathological finding.

Gestational trophoblastic disease is unique for its genetic origin, existence of ideal tumor marker -  $\beta$ hCG and extremely high sensitivity to chemotherapy. This makes it curable in spite of its high malignant potential.

Gestational trophoblastic disease appears as a result of abnormal gametogenesis and fertilization, so it represents natural neoplastic allograft with genetic material of another organism. Nongestational choriocarcinoma with primary ovarian or extragonadal localization also exists (1). Gestational trophoblastic disease can appear in any type of pregnancy.

Hydatiform mole appears as a result of proliferation of cytotrophoblast and syncytiotrophoblast with different degrees of hyperplasia and dysplasia, hydropic degeneration of chorionic villi and disintegration of blood vessels. It appears as partial or complete. Disorders in partial mole are mild and focal. Karyotype is triploid, 69,XXY. Disorders of complete mole are severe in the absence of fetus or embryo. Genetic material derives from duplication of paternal haploid set (46,XX). In some cases it occurs as a result of dispermic fertilization of an empty egg (46,XY).

Invasive mole (mole destruens, chorioadenoma destruens) has similar histological characteristics like a complete mole, but it is more aggressive, directly invades myometrium and its blood vessels, which often results in pulmonary embolisation. Distinction

Address correspondence to:

Dr. Milica Živaljević, Institute of Oncology Sremska Kamenica, Institutski put 4,  
21204 Sremska Kamenica, Yugoslavia

The manuscript was received: 08. 05. 2002.

Provisionally accepted: 28. 06. 2002.

Accepted for publication: 08. 07. 2002.

between mole and choriocarcinoma is difficult because of its similarity with malignant tissue: ability of invasion of myometrium, partial substitution of blood vessels endothelium and penetration in pulmonary circulation. Furthermore, degree of cellular atypia does not always correlate with tumor biological behavior.

Choriocarcinoma is a highly malignant epithelial tumor originating from all three types of trophoblastic cells. It often appears with hemorrhage and necrosis, and vascular spread in lungs, brain, liver, pelvis, vagina and spleen.

Placental site trophoblastic tumor is extremely rare, developing from intermediate cells of trophoblast, which produce human placental lactogen - hPL. Serum hCG levels are lower. It is relatively resistant to chemotherapy. The therapy of choice is surgery (2). Incidence of gestational trophoblastic disease varies widely in different populations. In Europe and North America it is quite rare. Hydatiform mole occurs approximately 1 in 1500 pregnancies, invasive mole 1 per 15,000 pregnancies, and choriocarcinoma 1 in 20,000 to 40,000 pregnancies (3).

Symptoms and signs of gestational trophoblastic disease are uterine bleeding after miscarriage, abortion or delivery, uterine enlargement greater than expected for the gestational date, bilateral theca lutein enlargement of the ovaries, hyperemesis, hyperthyroidism, and sometimes trophoblastic embolism. Patients with choriocarcinoma may also present with rather atypical symptoms, which may appear several years after pregnancy: cough, dyspnea, hemoptysis in pulmonary metastases, headache and neurological symptoms in brain metastases, acute abdomen in uterine perforation and bleeding. Level of serum hCG is always increased. In molar pregnancy the characteristic ultrasound shows multiple echoes. In choriocarcinoma, presence of tumor in uterus cannot always be determined.

Persistent gestational trophoblastic disease is diagnosed by:

- Plateauing, for 3 consecutive determinations, or rising hCG levels after evacuation of hydatiform mole
- Persistently elevated hCG levels after any pregnancy
- Histopathologic diagnosis of invasive mole, choriocarcinoma or placental site trophoblastic tumor
- Detection of metastases and elevated hCG levels

Persistent trophoblastic disease requires additional studies: magnetic resonance (MRI) of the brain, computed tomography (CT) scan of lungs, abdomen and pelvis, in addition liver, renal and thyroid function.

Because precise outcome is impossible to anticipate in hydatiform mole, or in lack of histology, the greatest significance lies in risk factors. Therefore, patients are classified into high risk or low risk groups according to risk factors. The Prognostic Group Clinical Classification system is used by most major US Trophoblastic disease centers (3).

**Table 1.** Prognostic group clinical classification for gestational trophoblastic tumors

I Nonmetastatic gestational trophoblastic tumor
II Metastatic gestational trophoblastic tumor
a. Low risk
β hCG < 40.000 mIU/ml serum or hCG < 100.000 IU/24-hour urine
Symptom present < 4 months
No brain or liver metastases
No prior chemotherapy
Pregnancy event is not term delivery
b. High risk
β hCG > 40.000 mIU/ml serum or hCG > 100.000 IU/24-hour urine
Symptom present > 4 months
Brain or liver metastases
Prior chemotherapeutic failure
Antecedent term pregnancy

Considering the fact that only anatomic criteria are insufficient for outcome prediction risk factors are included in FIGO classification (4). The American Joint Committee on Cancer (AJCC) has accepted modified TNM classification including following risk factors: hCG level > 100.000 IU/24 hour urine, and duration of disease > 6 months from termination of antecedent pregnancy (6).

**Table 2.** FIGO staging for trophoblastic tumors

Stage I – disease confined to uterus	
Ia – with no risk factors	
Ib – with one risk factors	
Ic – with two risk factors	
Stage II – tumor extending outside uterus but limited to genital structures (adnexa, vagina, broad ligament)	
IIa – with no risk factors	
IIb – with one risk factors	
IIc – with two risk factors	
Stage III – tumor extending to lungs with or without known genital tract involvement	
IIIa – with no risk factors	
IIIb – with one risk factors	
IIIc – with two risk factors	
Stage IV – All other metastatic sites	
IVa – with no risk factors	
IVb – with one risk factors	
IVc – with two risk factors	
Risk factors affecting staging include the following:	
-serums β hCG > 100.000 mIU/ml	
-duration of disease > 6 months from termination of antecedent pregnancy	

World Health Organization (WHO) adopted a modified prognostic system (5) based on patients' age, parity and type of antecedent pregnancy, time interval between antecedent pregnancy and trophoblastic tumor event, hCG level, paternal and maternal blood type, number and site of metastases, largest tumor mass, previous chemotherapy. Patients are classified in low risk, middle risk and high-risk groups.

Patients with non-metastatic trophoblastic disease can be treated with single-agent chemotherapy. Methotrexate is a therapy of choice. In some patients (20%) change of treatment is necessary because of the drug resistance, or because of drug induced toxicity (7). Second line therapy is dactinomycin, and in small number of cases multiagent therapy is needed. In patients who no longer wish to preserve fertility, hysterectomy is advisable as initial treatment, for it decreases the number of therapy courses and

its toxicity. Treatment of non-metastatic gestational trophoblastic disease is successful in all cases.

Initial therapy of low risk metastatic gestational trophoblastic disease is single agent chemotherapy with methotrexate. If resistance to methotrexate occurs, patients are switched to dactinomycin or multiagent chemotherapy. With adequate treatment, all patients are placed into remission. Resistance to primary therapy develops in 40-50% of treated patients, 10-15% of which demand multiagent therapy or surgery (3).

Multiagent chemotherapy is recommended in high-risk metastatic gestational trophoblastic disease: MAC (methotrexate, dactinomycin, cyclophosphamide), CHAMOCA (cyclophosphamide, hydroxyurea, actinomycin D, methotrexate, oncovine), EMA-CO (actinomycin D, etoposide, methotrexate, vincristine, cyclophosphamide) (8) with adjuvant radiation therapy, or surgery (hysterectomy, thoracotomy). Five-year survival in this stage of the disease is 60% for primary treatment and 30% for secondary treatment (8).

Determination of serum hCG levels enables extremely precise follow up of treatment, early diagnosis of persistent disease and metastasis.

## PATIENTS, MATERIALS AND METHODS

In Institute of Oncology in Sremska Kamenica, in Gynecologic department, 32 patients were treated from 1987 to 2001. Average age of these patients was 35.7 years, the range was 17 to 54 years.

Twenty-one patients presented in stage I, 2 patients in stage II, 4 in stage III, and 5 patients in stage IV of the disease, according to FIGO classification (Table 2). According to the Prognostic Group Clinical Classification 21 patient had non-metastatic disease and 11 patients had metastatic disease. Among patients with metastatic disease, 3 were with low risk, and 8 with high-risk disease (Table 5).

The most common metastatic sites were: lungs in 9 patients, brain in 3 patients, liver in 2 patients, vagina in 1 patient, ovaries in 1 patient.

The most common histological findings were choriocarcinoma, then hydatiform mole with no exclusion of choriocarcinoma, invasive mole, myometritis syntitialis, high-risk hydatiform mole (9).

**Table 3.** Histopathologic findings of cured patients

Pathohistologic findings:	No
1. Mola hydatidosa, high risk (WHO scoring system)	3
2. Myometritis syntitialis	1
3. Mola hydatidosa destruens	5
4. Mola hydatidosa destruens, but choriocarcinoma cannot be excluded	4
5. Choriocarcinoma	17
6. No pathohistology, only high level $\beta$ hCG and clinical finding	2

## RESULTS

Hysterectomy was performed on 14 patients with non-metastatic gestational trophoblastic disease. Average number of single agent courses was 2.1. Three patients who failed to respond to first line therapy with methotrexate were subsequently cured by second line therapy with dactinomycin. Two of these three patients had to change treatment because of drug resistance, and one of them because of drug induced toxicity. Four patients had initial surgical treatment in another institution.

**Table 4.** Distribution by stages (FIGO) and survival rate

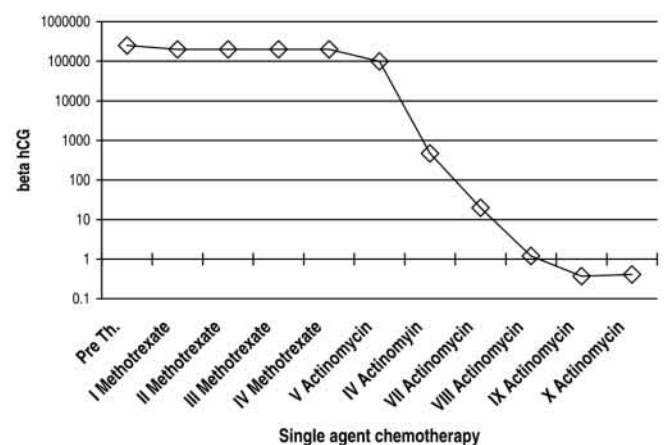
FIGO stage	A	B	C	No	Survival
I	13	8	-	21	100%
II	1	1	-	2	100%
III	2	2	-	4	100%
IV	1	3	1	5	0%
No	17	14	1	32	85%

Among the patients with low risk metastatic disease, one was cured with five courses of single agent therapy (methotrexate), other two received single agent therapy (methotrexate) followed by hysterectomy. One patient received second line therapy with dactinomycin (7 courses) because of drug resistance. Average number of courses was 5.6. Overall survival rate was 100%.

**Table 5.** Distribution by stages (Prognostic Group Clinical Classification - PGCC) and survival rate

Prognostic Group Clinical Classification	No of patients	Survival
Nonmetastatic disease	21	100%
Low risk metastatic disease	3	100%
High risk metastatic disease	8	63%

Patients with high-risk metastatic disease first were treated with single agent chemotherapy (methotrexate or dactinomycin). After that, they received multiagent chemotherapy (MAC and CP) in 8-11 courses. Five patients underwent hysterectomy, and one patient received radiotherapy for brain metastases. Overall survival rate of the patients with high-risk metastatic disease was 63%.



**Figure 1.** Beta hCG levels in patients with gestational trophoblastic disease during the chemotherapy



All five patients who died were in advance stage of disease:

1. Stage IV (FIGO)
2. High risk metastatic disease (Prognostic group clinical classification)
3. Prognostic score from 10 to 20 (mean, 15.8) HIGH RISK DISEASE (WHO)
4. Brain and liver metastases
5. Antecedent term pregnancy (3 patients)

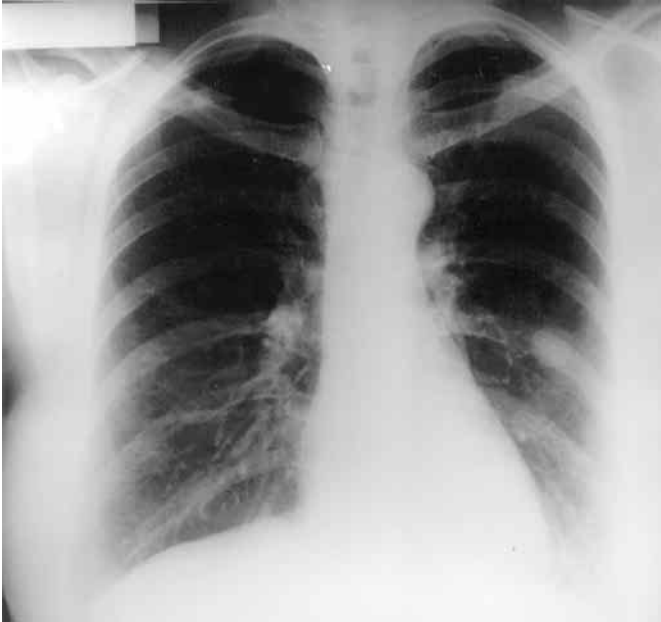

Figure 2. Lung metastases before chemotherapy

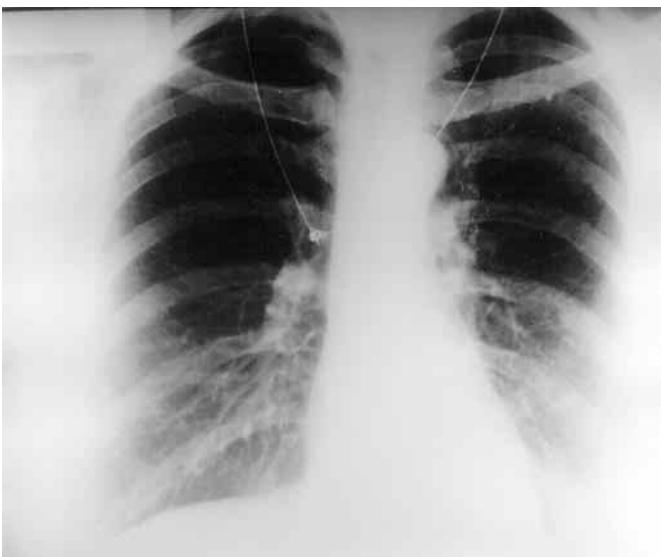


Figure 3. Lung metastases after chemotherapy

Overall five-year cure rate was 85% (Table 4). There is a significant distinction in survival between the patients with non-metastatic and patients with metastatic disease (100%, 63% respectively).

## DISCUSSION

Histology was not clearly determined in 5 cases. There was disagreement in histopathological findings in curetment, uterus specimen after hysterectomy and biopsy material of metastasis. Two patients were diagnosed without histology according to high HCG levels and clinical feature. These findings referring to the presence of different clinical entities of malignant trophoblastic disease confirm impossibility of clear distinction between mole and choriocarcinoma. Therefore, diagnosis should be made on the basis of high HCG level (11).

Therapy of choice is chemotherapy, single-agent therapy (methotrexate, dactinomycin) for non-metastatic disease and multi-agent therapy - EMA-CO, MAC (3) for high-risk metastatic disease. Surgical treatment and radiotherapy are necessary only in patients resistant to chemotherapy and in treatment of metastases. Follow up requires serial hCG testing. If rising or plateauing hCG levels for three consecutive determinations occur, patient should be treated with another chemotherapy protocol (12,13).

Significant difference in survival of patients with non-metastatic and metastatic disease (100%, 63% respectively) confirms that Prognostic Group Clinical Classification, used by most treatment centers in US and Europe, predicts disease outcome more accurately than anatomic system alone. All classification systems identify low risk and high-risk patients with statistically significant and equal efficiency. FIGO stage I - IIIa correlate with non-metastatic and low risk metastatic disease. Survival in stage IIIb and more, correlate with high-risk metastatic disease (13). WHO scoring system is not accurate in determining patients with low-risk metastatic disease in need for multiagent chemotherapy. WHO scoring system in patients with high-risk metastatic disease did not show significant difference between cured and deceased (9). All five patients who died were in stage IV (FIGO). They had high-risk metastatic disease (Prognostic Group Clinical Classification), with metastases in brain and liver. Three of them had antecedent term pregnancy. The mean prognostic score was 15.8 (WHO). The metastatic site and number of metastases is a relevant prognostic factor. Patients with vagina, vulva and lungs metastases have better chances for survival than those with liver and brain metastases. Prognostic factor is also duration of disease from termination of antecedent pregnancy. Biopsy of lung metastases was performed and diagnose was made in one of our patients, five years from termination of pregnancy.

Successful treatment of gestational trophoblastic tumor with chemotherapy resulted in a large number of women whose reproductive potential was retained despite exposure to teratogenic and toxic drugs. Chemotherapy has a minimal effect on the following pregnancies (14). However, these patients are at greater risk for

the development of mole in subsequent pregnancy (4.3%) (15). Some enlargement in number of stillbirths and cesarean sections was noticed (14).

## CONCLUSION

Our results are satisfactory, considering the fact that 9 patients developed metastatic disease, 7 patients were in stage III and stage IV (FIGO) and also, several patients had initial surgical treatment in another institution. Specificity and low incidence of this disease ask for the treatment to be carried out in specialized centers, as it is in developed countries (Trophoblastic Disease Centers).

## REFERENCES

1. Heaton GE, Matthews TH, Christopherson WM. Malignant trophoblastic tumors with massive hemorrhage presenting as a liver primary. A report of two cases. *Am J Surg Pathol* 1986;10:342-7.
2. Feltmate CM, Genest DR, Wise L, Bernstein MR, Goldstein DP, Berkovitz RS. Placental site trophoblastic tumor: a 17-year experience at the New England Trophoblastic Disease Center. *Gynecol Oncol* 2001;82(3):415-9.
3. Lurain JR. Hydatiform Mole and Gestational Trophoblastic Tumors. In: Piver MS, editor. *Gynecologic Oncology*. Boston: Little, Brown and Company; 1996. p. 171-87.
4. Kohorn EI. The new FIGO 2000 staging and risk factor scoring system for gestational trophoblastic disease: description and critical assessment. *Int J Gynecol Cancer* 2001;11(1):73-7.
5. World Health Organization Scientific Group: Gestational Trophoblastic Disease. WHO Tech Rep Ser 1983;692:1.
6. Gestational trophoblastic tumors. In: American Joint Committee on Cancer: *AJCC Cancer Staging Manual*. 5th ed. Philadelphia: Lippincott-Raven Publishers; 1997. p. 211-4.
7. Berkowitz RS, Goldstein DP, Bernstein MR. Methotrexate infusion and folinic acid in the primary therapy of non-metastatic gestational trophoblastic tumors. *Gynecol Oncol* 1990;36:56.
8. Di Saia PJ, Creasman WT. Gestational Trophoblastic Neoplasia. In: *Clinical Gynecologic Oncology*. 5th ed. St. Louis: C.V. Mosby Co; 1997. p. 180-201.
9. Lurain JR, Casanova LA, Miller D. Prognostic factors in gestational trophoblastic tumors. A proposed new scoring system based on multivariate analysis. *Am J Obstet Gynecol* 1991;164:611.
10. Tham KF, Ratnam SS The classification of gestational trophoblastic disease: a critical review. *Int J Gynaecol Obstet* 1998;1:539-49.
11. Ilancheran A. Optimal treatment in gestational trophoblastic disease. *Ann Acad Med Singapore* 1998;27(5):698-704.
12. Lurain JR. Management of high-risk gestational trophoblastic disease. *J Reprod Med* 1998;43(1):44-52.
13. Soper JT, Evans AC, Conaway MR. Evaluation of prognostic factors and staging in gestational trophoblastic tumor. *Obstet Gynecol* 1994;84:969-73.
14. Woolas RP, Bower M, Newlands ES, Seckl M, Short D, Holden L. Influence of chemotherapy for gestational trophoblastic disease on subsequent pregnancy outcome *Br J Obstet Gynaecol* 1998;105(9):1032-5.
15. Kim JH, Park DC, Bae SN, Namkoong SE, Kim SJ. Subsequent reproductive experience after treatment for gestational trophoblastic disease. *Gynecol Oncol* 1998;71(1):108-12.